

## Pathological Case of the Month

Tracy Prosen, MD; Catherine Craven, MD; Elizabeth McPherson, MD; Lyndon M. Hill, MD; W. Allen Hogge, MD

**A** 29-YEAR-OLD Middle Eastern gravida 2 para 1 woman was referred for perinatal evaluation after a routine ultrasound at 21 weeks' gestation was suspicious for skeletal dysplasia (long bones measured <fifth percentile). Bilateral clubbed feet were also noted. Her family history was unremarkable, without a history of skeletal dysplasia. A detailed ultrasound at our institution revealed shortening of all long bones (<fifth percentile) as well as shortening of the fetal foot. The ribs measured at the 50th percentile for gestational age, and the chest circumference was at the 10th to 25th percentile. Bilateral syndactyly of the third, fourth, and fifth digits of the hands was suspected. The hands also had a no-table separation of the second and third digits

*From the Departments of Genetics (Drs Prosen, McPherson, and Hogge), Maternal-Fetal Medicine (Drs Prosen and Hill), Perinatal Pathology (Dr Craven), and Ultrasound (Dr Hill), University of Pittsburgh Medical Center and Magee-Womens Hospital, Pittsburgh, Pa.*

(**Figure 1**). Bilateral clubbed feet with a rocker bottom appearance were noted. The right foot was thought to have polydactyly, and the toes of both feet appeared unusually long, except for the great toes, which appeared shortened. The fetal eyes protruded from the orbits. Results of fetal echocardiogram were normal. The karyotype was 46,XX. Cytogenetic studies for Robert syndrome were negative. An ultrasound obtained 13 days later had the additional finding of suspected polydactyly of both feet. The couple opted to terminate the pregnancy and underwent labor induction at 23 weeks' gestation. Autopsy findings (**Figure 2**) included short long bones of both the upper and lower extremities; short, stubby, tapered fingers; clinodactyly of the fifth fingers bilaterally; short, stubby, great toes bilaterally with wide space between the first and second toes; abnormal palmar creases; short, broad neck; micrognathia; and hypoplastic lungs. Radiography (**Figure 3**) revealed supernumerary ossification center between the proximal phalanx and the second metacarpal of the index finger.

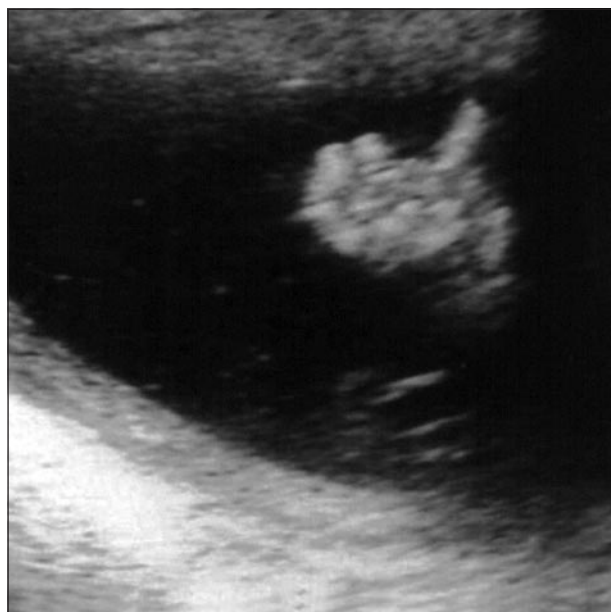

Figure 1.

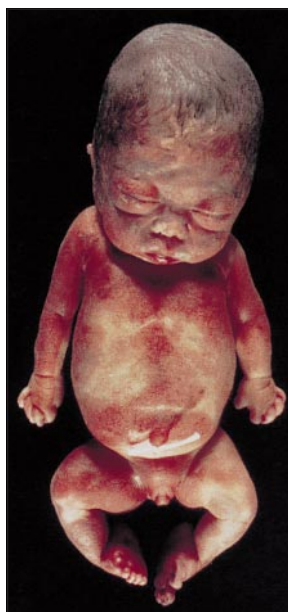

Figure 2.

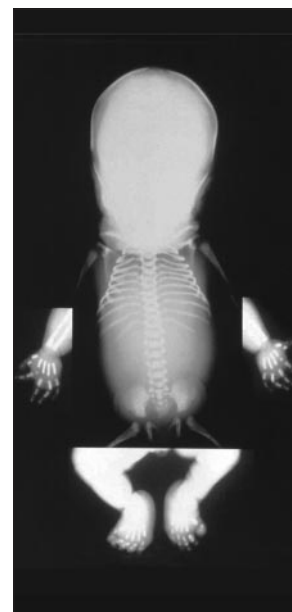


Figure 3.

# Diagnosis and Discussion

## Desbuquois Syndrome

**Figure 1.** Ultrasound of hand position.

**Figure 2.** Autopsy photograph.

**Figure 3.** Composite of radiographs of the fetus.

**D**esbuquois syndrome is a rare skeletal dysplasia with presumed autosomal recessive inheritance. It is characterized by micromelic dwarfism, narrow chest, vertebral and metaphyseal abnormalities, and advanced carpotarsal ossification. The findings in the hands are particularly distinctive with supernumerary ossification centers that cause deviation of the fingers. Dysmorphic facial features include a round flat face, prominent eyes, micrognathia, and long upper lip with flat philtrum. Severe, and even lethal, respiratory distress owing to the small thorax is not uncommon. Survivors have developmental delay and generalized joint laxity, with dislocatable knees, which is progressive.<sup>1-8</sup>

We suspected the diagnosis prenatally based on the extreme shortening of the long bones coupled with the abnormal positioning of the fetal hands. The presumed polydactyly, in retrospect, likely reflected the presence of supernumerary ossification centers. To our knowledge, this represents the first case of Desbuquois syndrome diagnosed prenatally in a family without a prior history of the disorder.

Accepted for publication June 22, 2000.

Presented as a poster at the American Society of Human Genetics Annual Meeting, San Francisco, Calif, October 20, 1999.

Reprints: Tracy Prosen, MD, Department of Genetics, Magee-Womens Hospital, 300 Halket St, Pittsburgh, PA 15213 (e-mail: tprosen@mail.magee.edu).

### REFERENCES

1. Beemer FA, Kramer PP, van der Harten HJ, Gerards LJ. A new syndrome of dwarfism, neonatal death, narrow chest, spondylometaphyseal abnormalities, and advanced bone age. *Am J Med Genet.* 1985;20:555-558.
2. Burton BK, Sumner T, Langer LO Jr, et al. A new skeletal dysplasia: clinical, radiologic, and pathologic findings. *J Pediatr.* 1986;109:642-648.
3. Gillissen-Kaesbach G, Meinecke P, Ausems MG, et al. Desbuquois syndrome: three further cases and review of the literature. *Clin Dysmorphol.* 1995;4:136-144.
4. Jequier S, Perreault G, Maroteaux P. Desbuquois syndrome presenting with severe neonatal dwarfism, spondylo-epiphyseal dysplasia and advanced carpal bone age. *Pediatr Radiol.* 1992;22:440-442.
5. Le Merrer M, Young ID, Stanescu V, Maroteaux P. Desbuquois syndrome. *Eur J Pediatr.* 1991;150:793-796.
6. Meinecke P, Spranger J, Schaefer E, Maroteaux P. Micromelic dwarfism with vertebral and metaphyseal abnormalities and advanced carpotarsal ossification: another observation. *Am J Med Genet.* 1989;32:432-434.
7. Shohat M, Lachman R, Gruber HE, et al. Desbuquois syndrome: clinical, radiographic, and morphologic characterization. *Am J Med Genet.* 1994;52:9-18.
8. McKusick VA, ed. *Online Mendelian Inheritance in Man, OMIN.* September 21, 1999. Baltimore, Md: Johns Hopkins University. National Center for Biotechnology Information Web site. Available at: <http://www.ncbi.nlm.nih.gov/omim>. Accessibility verified May 24, 2001.