

Pathological Case of the Month

Gail D. Cawkwell, MD, CM, PhD; Atilano G. Lacson, MD, FRCPC; Tony Kriseman, MB, B,Ch

A PREVIOUSLY healthy female infant developed vomiting, lethargy, poor oral intake, gray coloring, and decreased lower extremity movement at age 8 weeks. Respiratory acidosis prompted intubation. An electromyogram (EMG) showed disorganized muscle fibrillations consistent with inflammatory myopathy. Trials of intravenous immunoglobulin and methotrexate proved ineffective. Muscle weakness and stiffness pro-

From the Divisions of Allergy and Clinical Immunology (Dr Cawkwell) and Pulmonology (Dr Kriseman), Department of Pediatrics, and the Department of Pathology and Laboratory Medicine (Dr Lacson), All Children's Hospital, St Petersburg, Fla. Dr Cawkwell is now with Pfizer Inc, New York, NY.

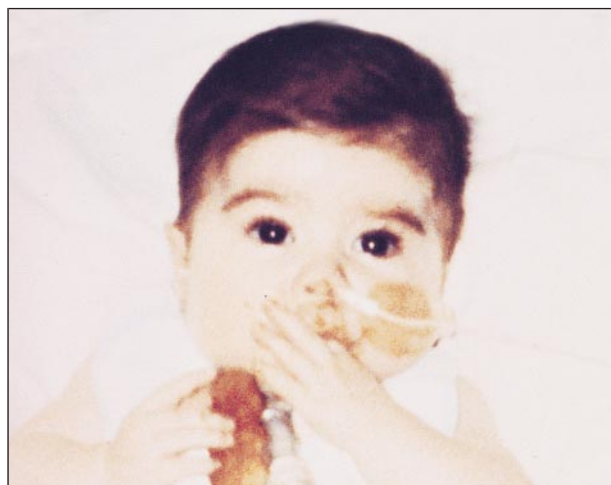


Figure 1.

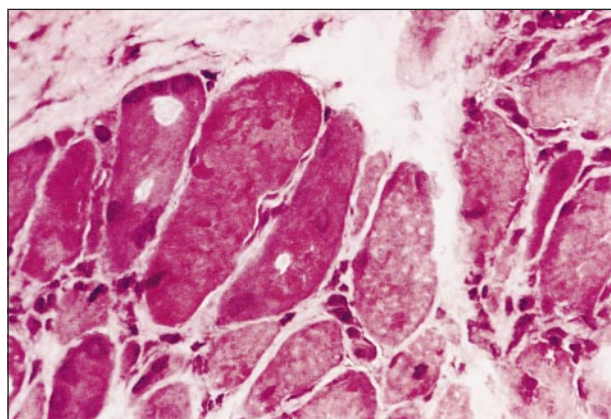


Figure 2.

gressed for the next 2 years (**Figure 1**), and creatine kinase levels were increased. At age 2 years, she lost all motion of the knees and elbows and developed spontaneous dislocation of the hips with preserved mobility of ankles and wrists. Impaired swallowing and decreased diaphragmatic and thoracic cage compliance resulted in a need for mechanical ventilation. The EMG of the right deltoid, vastus medialis, and tibialis anterior muscles at rest showed spontaneous fibrillations and sharp waves superimposed on normal-appearing motor unit action potentials. Nerve conduction studies were normal. Abdominal wall muscle biopsy from age 4 months showed marked fiber size variation and endomysial fibrosis; a deltoid muscle biopsy at age 9 months showed patchy sarcoplasmic granular basophilia with small eosinophilic inclusions (**Figure 2**). Severe fiber hypertrophy and atrophy with frequently necrotic and granular fibers characterized biopsy findings. Marked interstitial inflammation with myofiber phagocytosis and interstitial fibrosis complete the dystrophic picture (**Figure 3**). Viral studies were negative. Electron microscopic studies showed extensive, patchy Z-band transformation into granular, punctate densities interspersed with thin filaments. Subsarcolemmal autophagic vacuoles contained whorled membranes resembling myelin. The nuclei showed finely granular chromatin with no evidence of viral particles (**Figure 4**). The abnormal spontaneous muscle activity persisted during general anesthesia and during a curare-induced right common peroneal nerve block. By age 4 years, she lost all volitional motion except oral, ocular, and distal finger movements. At age 6 years (**Figure 5**), she remained at or above cognitive peer-appropriate levels with stable ventilatory requirements.

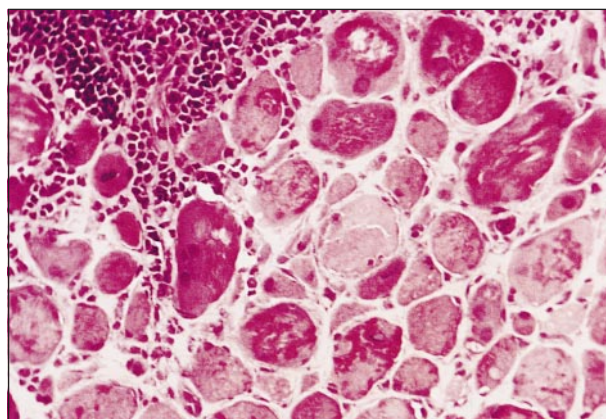


Figure 3.

Diagnosis and Discussion

Progressive Hypertonic Muscular Dystrophy

Figure 1. Age 6 months.

Figure 2. Cryostat sections of deltoid muscle obtained at age 9 months show random atrophy, marked fiber hypertrophy, and endomysial fibrosis. Note nucleomegaly with pale chromocenters resembling viral inclusions and small eosinophilic sarcoplasmic inclusions (hematoxylin-eosin, original magnification $\times 250$).

Figure 3. Note the extent of atrophy and hypertrophy. Large aggregates of lymphocytes are present. Some fibers are "disintegrating" with vacuolar degeneration and loss of sarcoplasmic detail (hematoxylin-eosin, original magnification $\times 100$).

Figure 4. Widespread granular appearance of Z-bands appear as small densities. The myofilamentous assembly is normal between. Mitochondria are unremarkable (uranyl acetate-lead citrate, original magnification $\times 10000$).

Figure 5. Age 6 years.

This patient, to our knowledge, represents the longest surviving patient with hypertonic muscular dystrophy (HMD), originally reported in 1994 in a Canadian Cree Indian population.¹ Her rigidity progressed until she could only move her eyebrows, and she became too stiff to ventilate. She died of respiratory failure at age 10³/₄ years. She had continued to be active in school and extracurricular activities until that

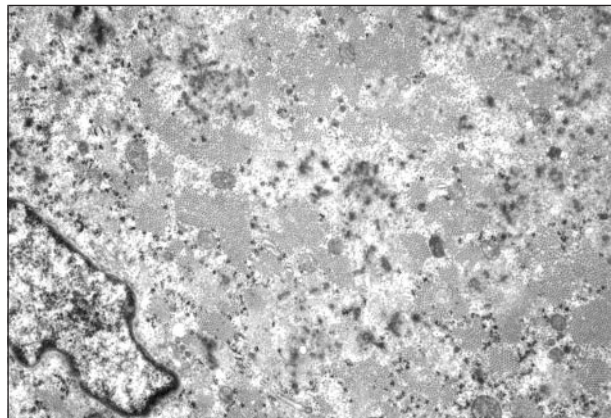


Figure 4.



Figure 5.

time. Case 8 of a recent report¹ showed no progression beyond age 18 months. That patient died at age 3¹/₂ years (Elizabeth Gibbings, MD, oral communication, June 1991). As in previous cases, our patient's rigidity became evident after the neonatal period.¹⁻³ The muscles remained rigid despite sequential motor unit blockade with curare, pancuronium, and total anesthetic nerve block. The fibrillation potentials on EMG resemble that seen in previously reported cases. Normal cognitive development and nerve conduction velocities further support the concept that the central and peripheral nervous systems are normal in HMD. Autopsy studies on previous cases support these findings as well.¹ Creek and Cree Indians are from geographically distinct regions. However, Creek Indians traded in regions that may have been inhabited by the Cree. We cannot, therefore, rule out a genetic transmission similar to those reported.

Features of HMD include progressive muscular dystrophy with granular transformation of Z-bands, best seen on longitudinal sections. This leads to disorganization of the adjacent myofilaments spanning several sarcomeres. A primary but segmental biochemical abnormality at the level of the Z-band organizational proteins might explain this phenomenon. Recent evidence suggests that the giant protein, titin, plays a major role in the development and subsequent arrangement of the myofilaments. During early muscle embryogenesis, this high-molecular-weight protein forms a punctate staining pattern by immunohistochemical analysis. On maturation, this protein is thought to unfold and ultimately span the region between the Z-line and M-line, evolving into a cross-striated pattern.^{2,3} It may play a role in maintaining muscle elasticity and normal ultrastructure.³ Alternatively, gene defects leading to loss of integrity in myofilament organization may contribute to muscle rigidity. The progressive muscle destruction may ultimately be due to a link to the membrane structural protein via the dystrophin axis. Further immunohistologic and population genetic studies using molecular techniques may help elucidate the pathophysiologic characteristics of this rare disease.

Accepted for publication June 3, 1999.

We thank Thomas O. Crawford, MD, for sharing his records and his support; Mr and Mrs Don Harper for their support and photographs; and Peter Steele, PhD, for doing the electron microscopic preparation.

Reprints: Gail D. Cawkwell, MD, PhD, Pfizer Inc, 235 E 42nd St, 219/4/34, New York, NY 10017.

REFERENCES

1. Lacson AG, Seshia SS, Samat HB, et al. Autosomal recessive, fatal infantile hypertonic muscular dystrophy among Canadian natives. *Can J Neurol Sci.* 1994; 21:203-212.
2. Trevenen CL, Hoogstraten J, DeGroot W, Seshia SS. Progressive muscular rigidity with respiratory failure in infancy. *Can J Neurol Sci.* 1979;6:379.
3. Dudley MA, Dudley SAW Jr, Bernstein LM, Hoogstraten J, Trevenen C. Progressive neonatal rigidity. *J Neuropathol Exp Neurol.* 1979;38:311.