Pathological Case of the Month

Ziwen Guo, MD, PhD; Sunita Chandra, MD

A FEMALE INFANT was delivered vaginally at 36 weeks' gestation to a 32-year-old gravida 2, para 1 mother. At birth, a subcutaneous mass measuring 6 × 5 × 2.5 cm in diameter was noted in the left parieto-occipital region of the scalp. A computed tomographic scan of the head showed a soft tissue subcutaneous dense lesion with calcification consistent with large hemangioma (**Figure 1**). Owing to ulceration of skin overlying the hemangioma, the lesion was surgically removed. Blood loss required multiple transfusions during surgery. The patient developed hypotension, asystolic rhythm, and died despite vigorous resuscitation efforts. A surgical specimen showed proliferation of blood-filled, thin-walled, endothelial-lined immature small vessels separated by connective tissue (**Figure 2**). At autopsy there were diffuse petechial hemorrhages on the front chest and both upper arms, ranging from 0.1 to 0.3 cm. Both lungs had diffuse petechial hemorrhages. The parenchyma was purple-red, firm, and uniform. Sections revealed collapsed alveoli and small airways with moderate to severe congestion and mild thickening of the septae. Most of the small vessels contained basophilic granular material, which was positive for factor VIII immunohistochemical staining (**Figure 3** and **Figure 4**). However, Carstair stain for fibrin was negative in the lung specimen. Platelet microthrombi were occasionally seen in the small vessels of the intestine and heart, while no thrombi were seen in the sections of skin, kidney, liver, or adrenal glands.

From the Department of Pathology and Laboratory Medicine, University of Wisconsin Hospital, Madison.

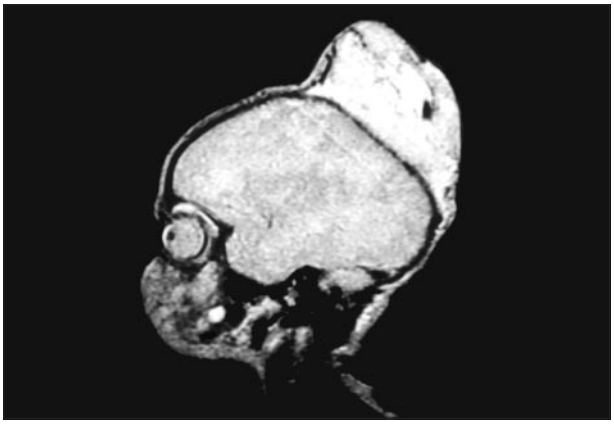

Figure 1.

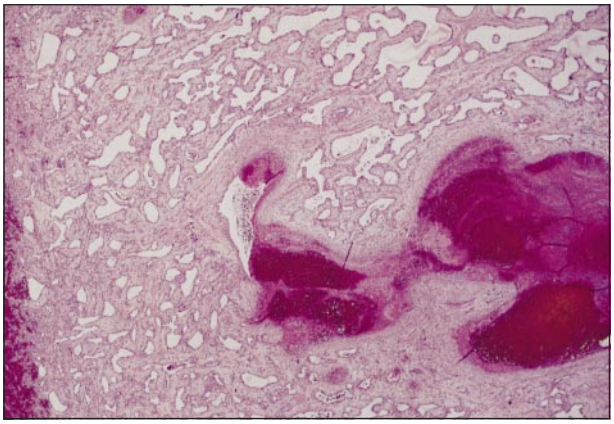

Figure 2.

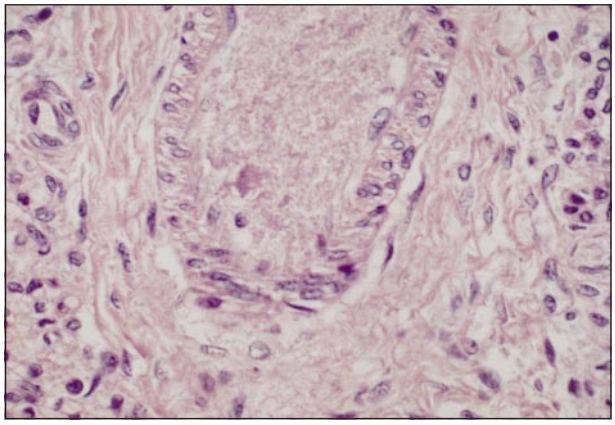

Figure 3.

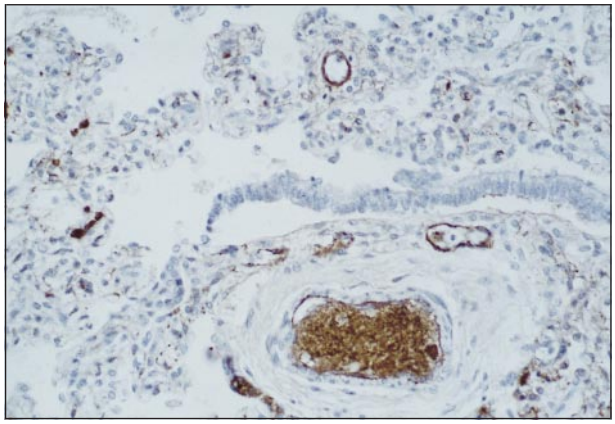

Figure 4.

©2001 American Medical Association. All rights reserved.
Downloaded From: http://archpedi.jamanetwork.com/ on 08/27/2015

Diagnosis and Discussion

Pulmonary Microvascular Platelet Thrombosis

Figure 1. *Computed tomographic scan of the head shows a subcutaneous dense soft tissue massive lesion with calcification (hemangioma).*

Figure 2. *The section of subcutaneous lesion of the head reveals proliferation of endothelial-lined blood vessels separated by scanty stroma and areas of hemorrhage.*

Figure 3. *The section of the lung shows small vessels containing intravascular basophilic granular thrombi.*

Figure 4. *The section of the lung reveals positive immunohistochemical staining for platelet factor VIII of intravascular basophilic granular thrombi (platelet thrombi).*

Microvascular platelet thrombosis is an uncommon condition. In several diseases, it is presumed to result in endothelial cell damage or dysfunction; intravascular coagulation plays an important pathogenic role. These disorders include thrombotic thrombocytopenic purpura and hemolytic uremic syndrome. The features of this disorder are the apparent selective consumption of platelets, usually without accompanying coagulation abnormalities, and the predominance of platelets as the occlusive material in the microvessels.[1] The organ systems with a high incidence of microvascular thrombosis associated with subsequent end-organ dysfunction include lungs, renal, central nervous system, liver, adrenal glands, and heart. Microvascular platelet thrombosis is often easily demonstrated in the pulmonary microcirculation, where it is customarily seen in association with intense vasoconstriction resulting from vasoconstrictive compounds released from platelets, including biogenic amines, adenine nucleotides, and kinins.[2] The presence of platelet microthrombi is also an early finding in patients with disseminated intravascular coagulation. The early deposited platelet-rich microthrombi are later replaced by fibrin-rich hyaline microthrombi.[3] The microscopic study of the lungs in our case showed the small vessels filled with platelet thrombi that were confirmed by factor VIII stain. Moreover, these thrombi were negative for fibrin stain. These observations suggest the possibility of selective consumption of platelet or early stage of disseminated intravascular coagulation. Several mechanisms of pathologic platelet aggregation have been proposed. The presence of a platelet-agglutinating protein in the plasma in the thrombotic thrombocytopenic purpura is postulated.[4] On the other hand, von Willebrand factor multimers in the blood and their involvement in the excessive and inappropriate agglutination of platelets have been suggested.[5] In our case, it is apparent that a multifactorial process resulted in the intraluminal platelet thrombus formation. The surgical resection of massive hemangioma may be associated with the release of platelet-agglutinating protein and/or von Willebrand factor multimers from damaged endothelial cells into the systemic circulation. It has been known that intravascular hemolysis of any origin is a common triggering event for disseminated intravascular coagulation. During hemolysis, the release of red blood cell adenosine diphosphate and/or red blood cell membrane phospholipoprotein may activate the procoagulant system.[2,6]

This infant had reportedly lost a substantial amount of blood during surgery and received multiple transfusions with the banked red blood cells over a short period. Intravascular hemolysis resulting from a massive transfusion, even a minor hemolytic transfusion reaction with release of red blood cell adenosine diphosphate or red blood cell membrane phospholipoprotein, can provide a trigger for activation of an episode of acute disseminated intravascular coagulation. The diffuse pulmonary intraluminal platelet thrombus formation resulted in the organ ischemia and hypoxia rather than end-organ hemorrhage, which most likely contributed to cardiopulmonary arrest of this patient toward the end of the surgical procedure.

Accepted for publication May 24, 1999.

Reprints: Sunita Chandra, MD, University of Wisconsin Hospital and Clinics, 600 Highland Ave, University of Wisconsin, Madison, WI 53792.

REFERENCES

1. Neame PB, Lechago J, Ling ET, Koval A. Thrombotic thrombocytopenic purpura: report of a case with disseminated intravascular platelet aggregation. *Blood.* 1973;42:805-814.
2. Bick RL. Disseminated intravascular coagulation and related syndromes: a clinical review. *Semin Thromb Hemost.* 1988;14:299-338.
3. Boyd JF. Disseminated fibrin-thromboembolism among neonates dying within 48 hours of birth. *Arch Dis Child.* 1967;42:401-409.
4. Siddiqui FA, Lian EC. Novel platelet-agglutinating protein from thrombotic thrombocytopenic purpura plasma. *J Clin Invest.* 1985;76:1330-1337.
5. Moake JL, Rudy CK, Troll JH, et al. Unusually large plasma factor VIII: von Willebrand factor multimers in chronic relapsing thrombotic thrombocytopenic purpura. *N Engl J Med.* 1982;307:1432-1435.
6. Surgenor DM. Erythrocytes and blood coagulation. *Thromb Diath Haemorrh.* 1974; 32:247-259.

©2001 American Medical Association. All rights reserved.
Downloaded From: http://archpedi.jamanetwork.com/ on 08/27/2015