SECTION EDITOR: BEVERLY P. WOOD, MD

Radiological Case of the Month

Renee E. Fox, MD; Jane E. Crosson, MD; Andrew B. Campbell, MD

A 2900-G, FULL-TERM MALE was born to a 24-year-old primiparous woman. Apgar scores were 8 and 8 at 1 and 5 minutes, respectively. At 24 hours of life, he had a grade III/VI systolic murmur at the lower left sternal border and developed circumoral cyanosis. His respiratory rate was 70 beats per minute; oxygen saturation, 70% to 85%. Arterial blood gas showed a pH of 7.45; P_{CO_2}, 24; P_{O_2}, 35; and base deficit, 5.6. After oxygen therapy was started with a fraction of inspired oxygen (F_{IO_2}) of 1.0, arterial blood gas levels were pH, 7.41; P_{CO_2}, 34; and P_{O_2}, 44. Blood samples were obtained, and ampicillin sodium and gentamicin sulfate were administered. His weight was 2810 g; height, 49 cm; and head circumference, 34.6 cm. Vital signs included a heart rate of 148 beats per minute; respirations, 44 per minute; and blood pressure, 66/31 mm Hg. A holosystolic murmur was heard at the lower left sternal border. An echocardiogram revealed normal cardiac structure and evidence of increased right ventricular pressure with persistent right to left shunting at the foramen ovale and ductus arteriosus.

Diagnosis was primary pulmonary hypertension (PH) in the newborn. Umbilical venous and arterial lines were placed. Chest radiography demonstrated pulmonary vascular congestion. Abdominal radiography was performed following placement of the umbilical venous catheter (**Figure 1**). The infant maintained an adequate P_{CO_2} level, but required an oxygen hood with F_{IO_2} of 0.85 to maintain saturation greater than 90%. He did not improve over the next 12 days, and his oxygen requirement was unchanged. His trachea was intubated, and he was ventilated with F_{IO_2} of 1.0 to decrease PH. On day 14, an echocardiogram and cardiac catheterization were performed (**Figure 2**).

From the Department of Pediatrics (Drs Fox and Crosson), Divisions of Neonatology (Dr Fox) and Cardiology (Dr Crosson), and the Department of Diagnostic Radiology (Dr Campbell), University of Maryland School of Medicine, Baltimore.

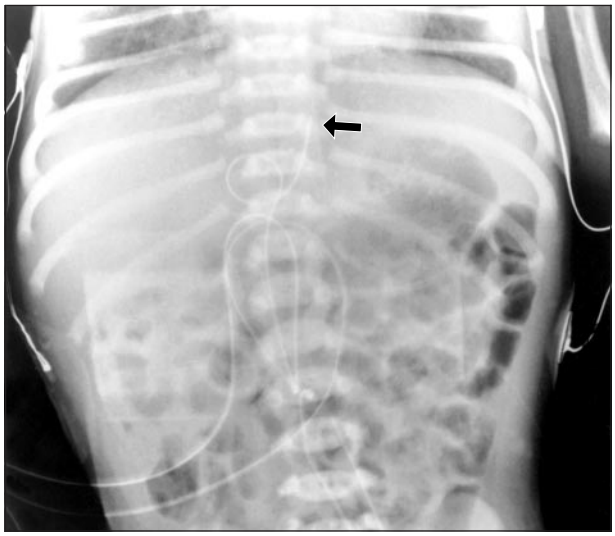

Figure 1.

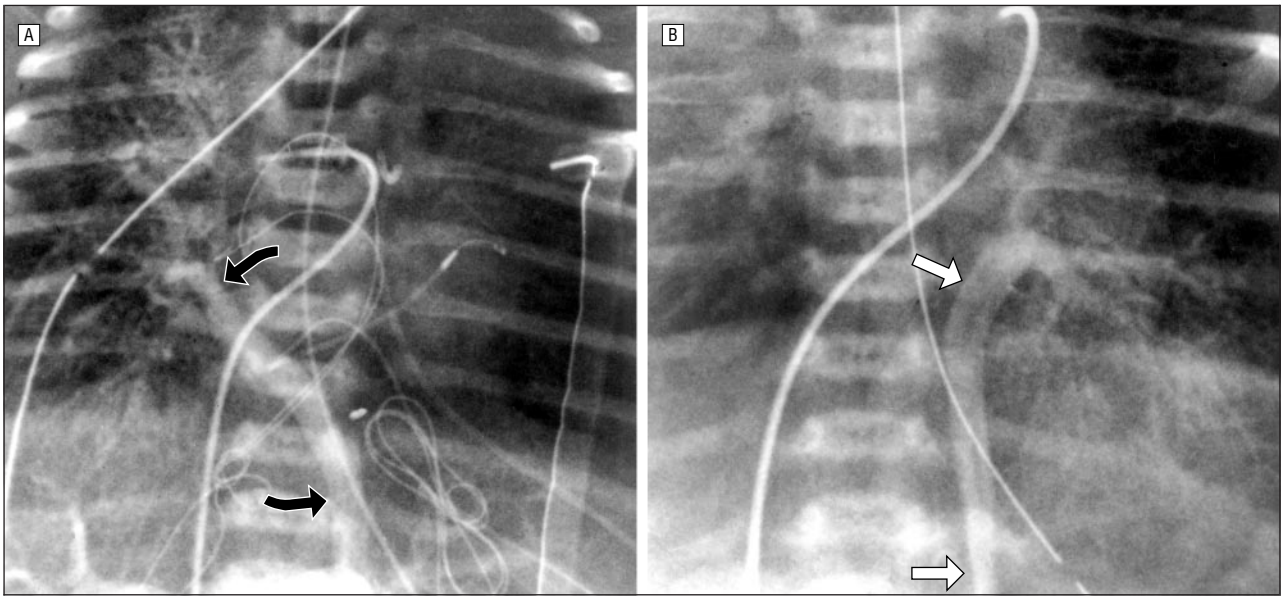

Figure 2.

©2001 American Medical Association. All rights reserved.
Downloaded From: http://archpedi.jamanetwork.com/ on 08/27/2016

Denouement and Discussion

Total Anomalous Pulmonary Venous Return

Figure 1. *The catheter coiled within the dilated left portal vein, with its tip directed toward the left diaphragm (arrow).*

Figure 2. *Cineangiograms performed in the venous phases of selective right (Figure 2A, curved arrows) and left (Figure 2B, open arrows) pulmonary artery injections demonstrated separate right and left pulmonary venous channels crossing the left diaphragm to join and enter the left portal vein.*

Of the many causes of cardiorespiratory distress in the neonate, total anomalous pulmonary venous return (TAPVR) is one of the most difficult to diagnose early. It constitutes 2% of all congenital cardiac defects and is an isolated lesion in two thirds of cases.[1] There may be associated cardiac defects. Classified into 2 major forms,[1] TAPVR is a congenital cardiac defect in which the pulmonary veins do not empty into the left atrium but anomalously drain into the right atrium. Blood flow is usually unobstructed when the common pulmonary vein connects with the superior vena cava, azygos vein, coronary sinus, or right atrium. Without obstructions to pulmonary venous return, the right side of the heart receives blood flow from the systemic and pulmonary venous systems. In the subdiaphragmatic form of TAPVR, there is almost always obstruction to blood flow.

The flow is obstructed in subdiaphragmatic TAPVR for several possible reasons. The common pulmonary vein passes through the diaphragm at the esophageal hiatus and can become compressed. There is resistance to flow as blood passes through the hepatic capillary bed before emptying into the inferior vena cava and returning to the right atrium. Blood flow through the ductus venosus becomes restricted as the ductus closes. An interatrial communication such as an atrial septal defect or patent foramen ovale must be present to provide the only route for blood to enter the left atrium, then the systemic circulation. A patent ductus arteriosus may also contribute to right to left shunting of blood from the pulmonary artery to the aorta in cases with PH. Infants with obstructive TAPVR may appear cyanotic and dyspneic in the first few hours or days of life. When there is obstruction to pulmonary venous return, pulmonary arteriolar constriction occurs as a reactive mechanism to prevent further pulmonary edema, and there is diminished pulmonary blood flow, a decreased oxygenated blood return, and increased cyanosis.

Right to left atrial and ductal shunting due to cyanotic congenital heart disease and primary PH of the newborn are confused with TAPVR in the neonatal period. Left-sided obstructive cardiac lesions occasionally mimic TAPVR. Clinical findings in infants with TAPVR vary considerably according to whether obstruction is present. The respiratory distress of an individual patient may vary, and the liver may be enlarged from passive congestion. Tachycardia, weak pulses, and cool extremities indicate low cardiac output secondary to hypoxia, acidosis, or obstruction to left ventricular filling. Murmurs may be absent if the pulmonary blood flow is limited by obstruction and/or persistently elevated pulmonary vascular resistance. If pulmonary resistance drops, a systolic murmur develops corresponding to excessive blood flow across the pulmonary valve with a diastolic murmur of flow across the tricuspid valve. The second heart sound is split.[1] The radiographic appearance of TAPVR also relates to the presence or absence of pulmonary venous obstruction. Cases without obstruction have increased pulmonary vascular markings and prominent pulmonary arteries due to increased blood flow.

When pulmonary venous obstruction is present, the most notable feature on radiography is a hazy, reticulogranular appearance of the lungs extending outward from the hila. The heart size in obstructive TAPVR is not increased since there is a decreased volume of blood returning to the heart. Infants with TAPVR do not demonstrate notable improvement in arterial oxygen saturation when breathing F_{IO_2} of 1.0. Although an arterial P_{O_2} higher than 150 mm Hg excludes cyanotic congenital heart disease, such rises can occur in TAPVR when blood returning to the right atrium streams rather than mixes.[2] Infradiaphragmatic TAPVR may be diagnosed by umbilical venous catheter samples with a higher venous than arterial saturation.[3] To diagnose TAPVR, the anomalous connection of the pulmonary veins to the systemic veins must be proved. Cardiac catheterization and angiography or magnetic resonance imaging may demonstrate the absence of the pulmonary veins entering the left atrium and depict the course and drainage of the anomalous pulmonary draining vessel.[4] Medical treatment of TAPVR aims to optimize the condition prior to surgery. Mechanical ventilation and prostaglandin E_1 decompress pulmonary circulation operating at suprasystemic pressures.[1] With severe obstruction, medical care is minimally effective, and rapid diagnosis followed by surgical correction is required.

Intracardiac repair carries significant mortality and morbidity from the development of postoperative PH that is intractable to therapy.[5] Following surgery this patient's PH was unresponsive to nitric oxide, epinephrine, isoproterenol, and amrinone. He died several days postoperatively.

Accepted for publication February 12, 1999.

Reprints: Renee E. Fox, MD, Department of Pediatrics, Room N5W68, University of Maryland School of Medicine, 22 S Greene St, Baltimore, MD 21201 (e-mail: rfox@peds.umaryland.edu).

REFERENCES

1. Bull C. Total anomalous pulmonary venous drainage. In: Long WA, ed. *Fetal and Neonatal Cardiology*. Philadelphia, Pa: WB Saunders Co; 1990:439-451.
2. Enriques AMC, McKay R, Arnold RM, Wilkinson JL. Misleading hyperoxia test. *Arch Dis Child*. 1986;61:604-606.
3. Long WA, Lawson EE, Harned HS, Henry GW. Infradiaphragmatic total anomalous pulmonary venous drainage. *Am J Perinatol*. 1984;1:227-235.
4. White CS, Baffa JM, Haney PJ, Pace ME, Campbell AB. MR imaging of congenital anomalies of the thoracic veins. *Radiographics*. 1997;17:595-608.
5. Cope JT, Banks D, McDaniel NL, Shockey KS, Nolan SP, Kron IL. Is vertical vein ligation necessary in repair of total anomalous pulmonary venous connection? *Ann Thorac Surg*. 1997;64:23-29.

©2001 American Medical Association. All rights reserved.
Downloaded From: http://archpedi.jamanetwork.com/ on 08/27/2016