SECTION EDITOR: BEVERLY P. WOOD, MD

Radiological Case of the Month

Hasnaa Jalou, MD; R. Gordon Hutcheon, MD; Albert Sanz, MD

A 2-MONTH-OLD infant, born by spontaneous vaginal delivery, was admitted for treatment of cellulitis of 1 toe as a result of a hair tourniquet. He was 3 kg at birth after a full-term pregnancy. His mother was aged 26 years, gravida 2, para 1, aborta 0 and had a seizure disorder for which she received divalproex sodium daily. She had learning disabilities and required special education. The infant's father, aged 60 years, is healthy. The infant was observed in the hospital for 1 week for an irregular heartbeat. He was well until he was admitted for treatment of cellulitis. Findings from physical examination revealed cutaneous lesions (**Figure 1**). He had a single café-au-lait lesion on his left arm. A cerebral magnetic resonance imaging scan (**Figure 2** and **Figure 3**) and an echocardiogram (**Figure 4**) were obtained. The cellulitis resolved after administration of antibiotic therapy, and he was discharged. At age 6 months, he developed infantile spasms.

From New York Medical College, Valhalla.

Figure 1.

Figure 2.

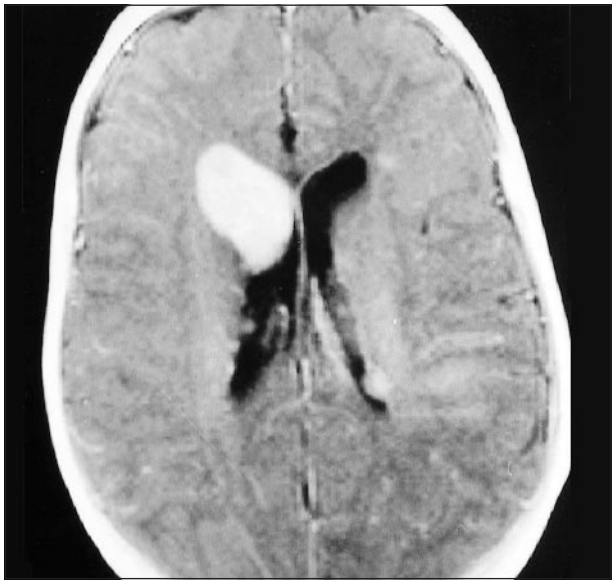

Figure 3.

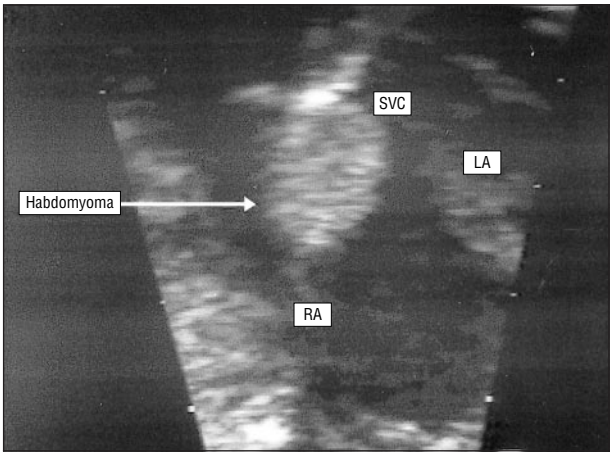

Figure 4.

©2001 American Medical Association. All rights reserved.
Downloaded From: http://archpedi.jamanetwork.com/ on 09/01/2015

Denouement and Discussion

Tuberous Sclerosis

Figure 1. *Hypopigmented lesions on the skin of the affected infant.*

Figure 2 and **Figure 3.** *Magnetic resonance image shows periventricular nodules and a giant cell astrocytoma of anterial horn of right ventricle.*

Figure 4. *Echocardiogram shows right atrial rhabdomyoma.*

Tuberous sclerosis (TS) is a condition that is inherited as an autosomal dominant trait and characterized by hamartomas involving multiple organ systems. The incidence is 1 in 10 000 births. Clinical presentations vary widely. Cutaneous involvement is a frequent sign of TS. Hypomelanotic macules are the earliest skin manifestations (Figure 1 and Figure 2) and are most apparent when the surrounding skin is dark. They can be identified clearly with use of a Wood light. The shape is polygonal or ash-leaf, and on occasion they occur as groups of numerous small (1-3 mm) white macules.[1] Other cutaneous lesions include connective tissue hamartomas with facial angiofibroma (adenoma sebaceum) present in at least half of all patients with TS. They are localized over the nasal bridge and cheeks in a butterfly distribution and appear between age 5 years and puberty. Ungual fibromas, Shagreen patch, and forehead fibrous plaque[1] are cutaneous findings.

Severe central nervous system involvement is characteristic of TS. Cortical tubers and an astrocytoma are demonstrated in Figure 3 and Figure 4. The brain hamartomas may cause complex or partial seizures that evolve over time.[1] The tubers, which consist of sclerotic tissue, are located throughout the cerebral hemispheres. These tubera are histogenetic malformations of both neuronal and glial elements with decreased neurons, increased glia, and abnormal giant heterotopic cells. Approximately 6% to 14% of patients with TS will develop giant cell astrocytomas during the first 2 decades of life.[2] Contrast-enhanced magnetic resonance images or computed tomographic (CT) scans help to distinguish a giant cell astrocytoma from other cerebral lesions. Of children with infantile spasms, 10% will have TS.[3] Mental retardation, autism, attention-deficit/hyperactivity disorder, or a combination of these conditions are seen in TS.[4] Cerebrovascular anomalies are rare, but a few cases of cerebral arterial ectasia and giant fusiform aneurysm formation in children have been reported. Magnetic resonance angiography may be used for diagnosis, which prevents obtaining biopsy specimens of a vascular lesion.[5]

The cardiovascular system is affected in TS. Multiple clinically silent cardiac rhabdomyomas are found in affected infants (Figure 5). The masses are most often located in the ventricles where they may cause arrhythmias or outflow obstruction of one or both ventricles.[1] The rhabdomyomas have been found to resolve spontaneously in infancy or by early adolescence.[3] Renal involvement, common in TS, is characterized by renal cysts. The cysts are bilateral, multiple, of varying sizes, and usually asymptomatic.[1] Although they mimic autosomal dominant cystic kidney disease, they can be distinguished histopathologically. Solid masses are angiolipomas, which are vascular tumors consisting of smooth muscle, adipose tissue, and fibrous tissue. The angiomyolipomas are present more often in women.[2] There is a small risk of degeneration of the renal lesion into renal cell carcinoma.[1] Other organ systems may be involved. Retinal lesions range from the classic mulberry retinal astrocytoma to the more common plaquelike hamartomas and achromatic areas.[2] Asymptomatic microhamartomatous polyps of the rectum occur in three quarters of all patients with TS, and hepatic hamartomas occur in about one quarter of all children with TS. Dental enamel pitting is seen in 90% of patients with TS.[1] Pulmonary involvement, estimated to occur in fewer than 1% of all affected individuals, can be fatal within 5 years of the onset of symptoms (recurrent spontaneous pneumothorax or progressive respiratory failure).[6]

A variety of imaging studies are indicated when a diagnosis of TS is suspected. Neuroradiologic evaluation helps establish or confirm the clinical diagnosis and is useful for screening parents of affected children. Calcified subependymal nodules in the cerebrum, located within or near the caudate nucleus, are the single most specific lesion noted by CT.[2] Cranial CT scans may appear normal in the first year of life, before calcification of the lesions has occurred.[7] Magnetic resonance imaging is the neuroimaging procedure of choice for the diagnosis of TS.[2] It is more sensitive than a CT scan in the detection and delineation of cortical tubera, although CT is superior in demonstrating calcification of subependymal nodules.[2] Abdominal ultrasonography is a sensitive technique for the detection of renal and hepatic angiomyolipomas.[7]

Genes implicated in the origin of TS have been identified (*TSC1* on chromosome 9 and *TSC2* on chromosome 16). Their products are thought to have tumor suppressor activity that is reduced by the presence of mutations.[4] The evaluation of an infant or child suspected of having TS requires active involvement of the radiologist when cranial magnetic resonance imaging or CT are used to look for typical intracranial lesions; renal ultrasound and an echocardiogram are also components of the evaluation. Because the condition has an autosomal dominant pattern of inheritance with variable expressivity, the same studies may be indicated for the parents and siblings of an affected child. Clinical issues such as treatment of seizures and developmental delays are addressed for each child.

Accepted for publication February 18, 1999.

Reprints: Hasnaa Jalou, MD, New York Medical College, Munger Pavilion, Room 106, Valhalla, NY 10595.

REFERENCES

1. Kwiatkowski DJ, Short MP. Tuberous sclerosis. *Arch Dermatol.* 1994:130;348-354.
2. Roach ES. Neurocutaneous syndromes. *Pediatr Clin North Am.* 1992;39;591-620.
3. Webb DW, Osborne JP. Tuberous sclerosis. *Arch Dis Child.* 1995;72;471-474.
4. Van Slegtenhorst M, de Hoogt R, Hermans C, et al. Identification of the tuberous sclerosis gene TSC1 on chromosome 9q34. *Science.* 1997;277:805-808.
5. Spangler WJ, Cosgrove GR, Moumdjian RA, Montes JL. Cerebral arterial ectasia and tuberous sclerosis: case report. *Neurosurgery.* 1997;40:191-194.
6. Shepherd CW, Gomez MR, Lie JT, Crowson CS. Causes of death in patients with tuberous sclerosis. *Mayo Clin Proc.* 1991;66:792-796.
7. Truhan AP, Filipek PA. Magnetic resonance imaging: its role in the neuroradiologic evaluation of neurofibromatosis, tuberous sclerosis, and Sturge-Weber syndrome. *Arch Dermatol.* 1993;129:219-226.

©2001 American Medical Association. All rights reserved.
Downloaded From: http://archpedi.jamanetwork.com/ on 09/01/2015