SPECIAL FEATURE

Pathological Case of the Month

Troy L. Haleman, MD; Martin S. Cogen, MD; Carlos A. Galliani, MD

AN 11-YEAR-OLD asymptomatic white girl was seen for a pigmented conjunctival lesion of the left eye. The parents reported that the lesion had become noticeable 3 weeks earlier. Her ophthalmologic history was remarkable for infantile left dacryostenosis, which resolved spontaneously at 6 to 8 months of age, and mild myopia, corrected with lenses since age 10 years. On examination, a slightly elevated, movable, tan-yellow nodule with a deep brown area was observed on the bulbar conjunctiva near the inner canthus of the left eye (**Figure 1**). No other bulbar or palpebral pigmentation was noted. An excisional biopsy was performed. A 0.5 × 0.3 × 0.15-cm conjunctival specimen was white-yellow and contained a slightly eccentric dark brown pigmented lesion (**Figures 2**, **3**, and **4**).

From the Departments of Ophthalmology (Drs Haleman and Cogen) and Pathology (Dr Galliani), University of Alabama at Birmingham School of Medicine.

Figure 1.

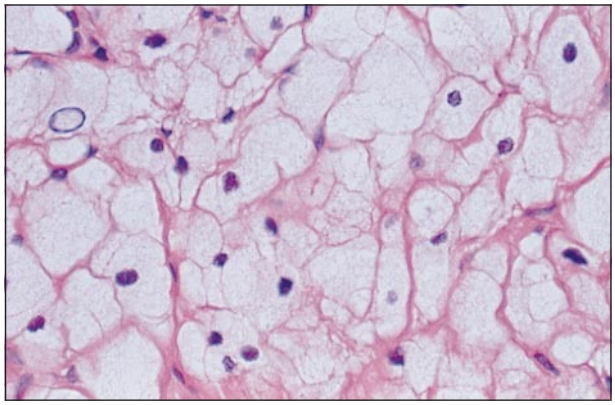

Figure 3.

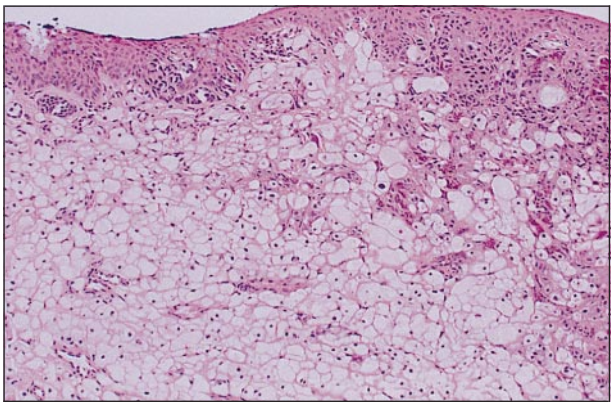

Figure 2.

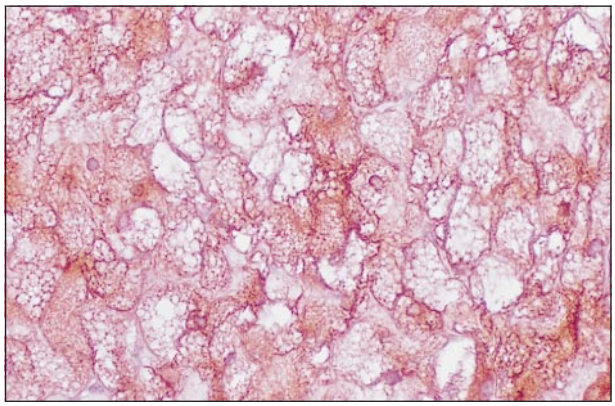

Figure 4.

©2001 American Medical Association. All rights reserved.
Downloaded From: http://archpedi.jamanetwork.com/ on 10/07/2015

Diagnosis and Discussion

Balloon Cell Nevus of the Conjunctiva

Figure 1. *Left eye bearing a discrete, slightly raised dark brown lesion with well-outlined borders arising from the medial interpalpebral conjunctival angle, the semilunar fold.*

Figure 2. *Beneath an intact conjunctival epithelium is a predominant population of balloon cells. Toward the right margin, nests of conventional nevus cells are seen in the lower layers of the conjunctival epithelium and in the substantia propria (compound nevus). There is a light sprinkling of melanophages (hematoxylin-eosin, original magnification ×100).*

Figure 3. *At higher magnification, the striking ballooned character of the nevus cells is evidenced by their polyhedral, ample microvesicular cytoplasms (ultrastructurally corresponding to coalescing enlarged and vacuolated melanosomes) with sparse to absent pigment, distinct cytoplasmic membranes, and small, hyperchromatic, round to slightly scalloped central nuclei, and rare intranuclear vacuole or pseudoinclusion (hematoxylin-eosin, original magnification ×400).*

Figure 4. *Immunohistochemical staining using anti–S100 protein shows diffuse and strong positive reaction in the balloon cells. Immunohistochemical staining for anti–HMB-45 was negative (anti–S100 protein immunohistochemical stain, ×400).*

Balloon cell nevus is a rare histopathologic curiosity with no distinguishing features for the clinical observer. Because of their striking microscopic characteristics, balloon cells are readily recognizable. However, these altered nevus cells can be confused with xanthoma cells, brown adipocytes/hibernoma cells, and potentially with other clear cell tumors such as clear cell hidradenoma, metastatic clear cell sarcoma, and renal cell carcinoma. Therefore, immunohistochemical and/or ultrastructural confirmation may be required.

The conjunctiva is a diaphanous mucous membrane that covers the anterior surface of the eye and lines the inner surface of the eyelids. The conjunctival epithelium of the semilunar plica (crescentic fold located in the medial interpalpebral angle of the eye, a presumed remnant of the nictitating membrane) minimally differs from the anterior surface conjunctiva in that it possesses a more prominent population of goblet cells. The conjunctival epithelium contains dendritic melanocytes in the basal layers and may contain nevus cells of the common, epithelioid, and fusiform types. Thus, the conjunctiva is the seat of a wide spectrum of benign and malignant pigmented lesions equivalent to those affecting the skin, including balloon cell nevi, Spitz nevi, blue and cellular nevi, combined nevi, and malignant melanoma.[1,2] With only minor modifications adapted to the microscopic anatomy, the nomenclature applied to conjunctival nevi is comparable to that used for the skin. In descending order, the most common locations for benign conjunctival nevi are juxtalimbal, epibulbar, the plica, the caruncle, and the eyelid margin.

Possibly all conjunctival melanocytic nevi are congenital and may become noticeable at any time during the first and second decades, but most will be detected around the age of puberty when the nevi acquire pigment and nevus cell proliferation is promoted by hormonal changes. The first case of balloon cell nevus of the conjunctiva recorded in the US medical literature was that of a 39-year-old woman (born about the time of publication of the original description of balloon cell nevus by Miescher[3]) who was observed, by a different examiner, to have a pigmented conjunctival lesion at age 11 years.[4] Since then, only a paucity of cases have been reported. Conjunctival nevi undergo profound changes as the nevus cells evolve and descend into the superficial substantia propria. On occasions, and chiefly during adolescence, conjunctival nevi may elicit a florid lymphocytic response and raise the suspicion of melanoma. Benign conjunctival nevi in infants, children, and adolescents may exhibit cytologically worrisome features.[5] Balloon cell nevus of the conjunctiva is an uncommon and puzzling phenomenon identifiable histologically by their voluminous microvesicular cells, but has no salient clinical characteristics and does not constitute a clinicopathologic entity.

Accepted for publication March 3, 2000.

This study was supported by an unrestricted grant from the Alabama Eye Institute and Research to Prevent Blindness Inc.

Reprints: Martin S. Cogen, MD, University of Alabama at Birmingham School of Medicine, 700 S 18th St, Suite 511, Birmingham, AL 35233.

REFERENCES

1. Folberg R, Jakobiec FA, Bernardino VB, Iwamoto T. Benign conjunctival melanocytic lesions: clinicopathologic features. *Ophthalmology*. 1989;96:436-461.
2. Farber M, Schultzer P, Mihm MC Jr. Pigmented lesions of the conjunctiva. *J Am Acad Dermatol*. 1998;38:971-978.
3. Miescher G. Umwandlung von Naevuszellen in Talgrusenzellen? *Arch Dermatol Syphil*. 1935;171:119-124.
4. Pfaffenbach DD, Green WR, Maumenee AE. Balloon cell nevus of the conjunctiva. *Arch Ophthalmol*. 1972;87:192-195.
5. Margo CE, Roper DL, Hidayat AA. Borderline melanocytic tumor of the conjunctiva: diagnostic and therapeutic considerations. *J Pediatr Ophthalmol Strabismus*. 1991;28:268-270.

©2001 American Medical Association. All rights reserved.
Downloaded From: http://archpedi.jamanetwork.com/ on 10/07/2015