SECTION EDITOR: WALTER W. TUNNESSEN, JR, MD

Picture of the Month

Christiane Stahl, MD; Robert Cohen, MD

A 19-YEAR-OLD young adult had a 3-month history of body aches and a 1-month history of swelling of the left clavicle. He also reported fever, cough, and night sweats. The body aches included migratory pains in his left clavicle, lower ribs, lower back, right ankle, and upper arms. On physical examination, tender, warm, firm swelling of the left medial clavicle (**Figure 1**), right posterior lateral malleolus, and proximal left fibula were found. Findings from the remainder of the examination, including a slitlamp examination of the eyes, were unremarkable. Three weeks later, he developed bilateral parotid swelling that felt woody to palpation. Chest radiography findings were unremarkable except for marked hilar adenopathy. Additional studies included a technetium-Tc 99m bone scan (**Figure 2**) and computed tomography of the chest (**Figure 3**).

From the Division of Adolescent Medicine, Department of Pediatrics (Dr Stahl), and the Division of Pulmonary Medicine, Department of Internal Medicine (Dr Cohen), Cook County Hospital, Chicago, Ill.

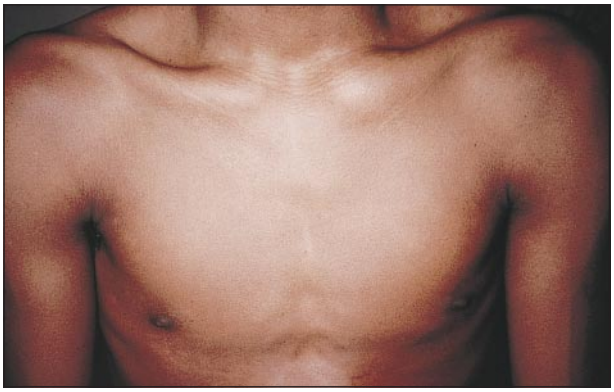

Figure 1.

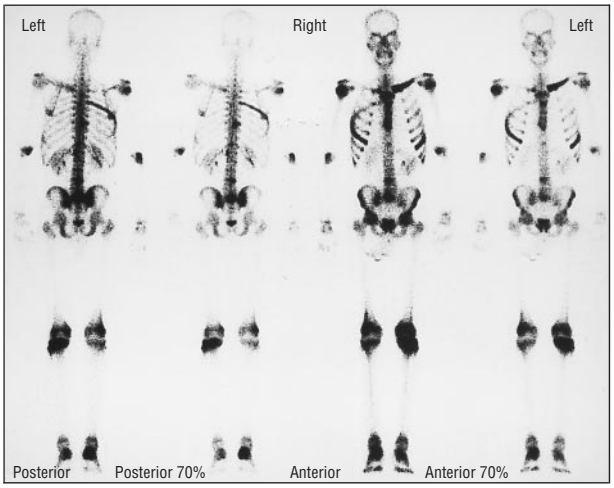

Figure 2.

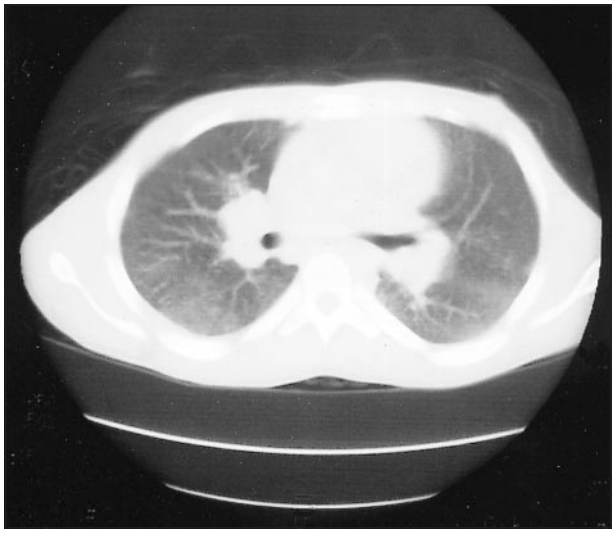

Figure 3.

©2000 American Medical Association. All rights reserved.
Downloaded From: http://archpedi.jamanetwork.com/ on 10/08/2015

Denouement and Discussion

Sarcoidosis With Bone Involvement

Figure 1. *The left medial clavicular area appeared swollen.*

Figure 2. *A technetium Tc 99m bone scan showed multiple areas of increased uptake in the ribs, thoracic and lumbar spine, left knee, left clavicle, right ankle, and right shoulder.*

Figure 3. *Computed tomography of the chest revealed anterior mediastinal, bilateral hilar, and azygoesophageal lymphadenopathy as well as thickened interstitial markings and patchy ground glass opacity of the lung fields.*

Additional laboratory examination results included a white blood cell count of 11.8×10^9/L with a differential count of 55% band forms; hemoglobin, 105 g/L; hypercalcuria, 260 mg/24 h; and an elevated angiotensin-converting enzyme level, 94 U/L. A bone marrow aspirate showed noncaseating granulomas on routine staining. Pulmonary function testing revealed moderately severe restrictive lung disease with a diffusion impairment.

Sarcoidosis, a multisystem disease of unknown cause, has a peak incidence between ages 20 and 40 years, but it is not rare in adolescents. Kendig[1] observed 2 age peaks, 1 in adolescence and 1 in young adulthood. Regional and ethnic variations in incidence are marked; the incidence ranges from 30 to 640 per 100 000 population, with the highest incidence in the southeastern rural United States, particularly among African Americans.[2]

CLINICAL MANIFESTATIONS

The diagnosis of sarcoidosis is most commonly made when chest radiography, obtained for unrelated reasons or pulmonary symptoms, unexpectedly reveals hilar adenopathy. Patients in the pediatric age group are more likely than adults to have multiple symptoms, signs, and abnormalities on laboratory studies, including cough (50%), fatigue (50%), bone and joint pain (45%), parotid enlargement (40%), fever (40%), hypercalcuria (80%), hypergammaglobulinemia (90%), and restrictive impairment on pulmonary function testing (50%).[3] Elevated serum levels of angiotensin-converting enzyme have been reported in 80% of children with sarcoidosis.[4] Noncaseating granulomas found in affected tissues are the hallmark of sarcoidosis but are not specific for the disease.

SKELETAL INVOLVEMENT

Musculoskeletal symptoms are common in sarcoidosis, but bone involvement detected on radiography is reported to be uncommon, affecting 1% to 13% of patients.[5] The bones of the hands and feet are the most common sites of detected abnormalities.[5] Bone involvement is reported to portend a worse prognosis, with a mortality rate 4 times higher in patients who are detected to have abnormalities on bone radiography than in those with normal findings.[4] Almost half of patients have no signs or symptoms related to bone involvement despite the abnormal radiographic findings.[4] Of patients with symptomatic osseous sarcoidosis, the most common site of involvement is the vertebrae, and the duration of illness before the onset of musculoskeletal symptoms is a year or less.[6]

Bone involvement is much more commonly detected with the use of bone scans than with routine radiography.[7-10] Most patients with abnormalities detected by bone scan have related symptoms. Bone scans may also detect muscle involvement of sarcoidosis.[11] Magnetic resonance imaging may be even more sensitive in detecting bone involvement. Three children with fever of unknown origin and leg pain who had normal findings on bone radiography and bone scans were found to have multifocal nodular lesions in their tibiae on magnetic resonance imaging.[12] Bone involvement in sarcoidosis may be more common than previously reported, particularly in patients with musculoskeletal symptoms. Bone scans and magnetic resonance imaging may increase the likelihood of detecting bony abnormalities.

Accepted for publication February 4, 2000.

Reprints: Christine Stahl, MD, Division of Adolescent Medicine, Cook County Hospital, 1900 W Polk St, Room 1112, Chicago, IL 60657.

REFERENCES

1. Kendig EL Jr. Sarcoidosis in children: personal observations on age distribution. *Pediatr Pulmonol.* 1989;6:69-70.
2. Patishall EN, Denny FW, Kendig EL. Sarcoidosis. In: Chernick V, Boat TF, Kendig EL, eds. *Disorders of the Respiratory Tract in Children.* Philadelphia, Pa: WB Saunders Co; 1998:934-946.
3. Patishall EN, Strope GL, Spinola SM, Denny FW. Childhood sarcoidosis. *J Pediatr.* 1986;108:169-177.
4. Neville E, Carstairs LS, James DG. Sarcoidosis of bone. *Q J Med.* 1977;182:215-227.
5. James DG, Neville E, Carstairs LS. Bone and joint sarcoidosis. *Semin Arthritis Rheum.* 1976;6:53-81.
6. Silver H, Shirkhoda A, Simon D. Symptomatic osseous sarcoidosis with findings on bone scan. *Chest.* 1978;73:238-241.
7. Rohatigi P. Radioisotope scanning in osseous sarcoidosis. *AJR Am J Roentgenol.* 1980;134:189-191.
8. Cinti D, Hawkins H, Slavin J. Radioisotope bone scanning in a case of sarcoidosis. *Clin Nucl Med.* 1985;10:192-194.
9. Sweeney D, Roberson J. Osseous and central nervous system sarcoidosis: scintigraphic and radiographic findings. *J Nucl Med.* 1995;36:464-466.
10. Benelhadj S, Patrois F, Duet M, Berolatti B, Mundler O. Radioisotope bone scanning in chronic osseous sarcoidosis. *Clin Nucl Med.* 1996;21:371-374.
11. Krubsack A. Three-phase bone scan in muscular sarcoidosis [letter]. *J Nucl Med.* 1991;32:1829-1830.
12. Gedalia A, Shetty A, Ward K, Correa H, Heinrich S. Role of MRI in diagnosis of childhood sarcoidosis with fever of unknown origin. *J Pediatr Orthop.* 1997;17:460-462.

©2000 American Medical Association. All rights reserved.
Downloaded From: http://archpedi.jamanetwork.com/ on 10/08/2015