

SECTION EDITOR: BEVERLY P. WOOD, MD

Radiological Case of the Month

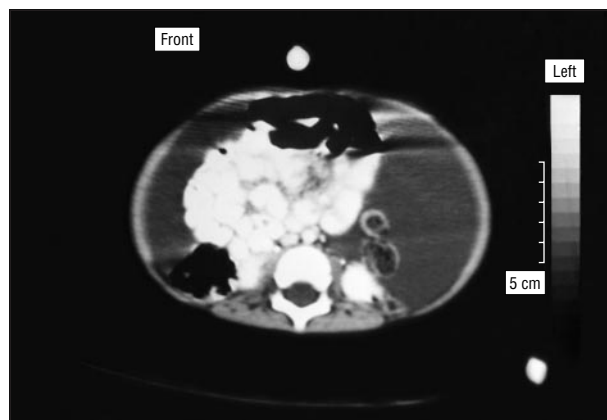
Hassib Narchi, MD, FRCP, FRCPC

A PREVIOUSLY healthy 15-month-old boy had a 3-month history of abdominal distension without associated pain, vomiting, or abnormal stools. His developmental milestones and growth parameters were normal, and findings from the family history were unremarkable. Findings from physical examination revealed normal nutritional status, absence of pallor or jaundice, normal vital signs, and normal cardiorespiratory examination results. Moderate abdominal distension with shifting dullness and fluid thrill was noted, but the flanks were not bulging. There was no hepatosplenomegaly, bruising, or peripheral edema.

The following laboratory results were normal: tuberculin test; complete blood cell count; erythrocyte sedimentation rate; serum albumin and total protein levels; creatinine levels; electrolytes; liver function tests; levels for amylase, lipase, calcium, and phosphorus; anti-

nuclear antibodies; and coagulation studies. The serum cholesterol level was 4.3 mmol/L (166 mg/dL), and triglyceride levels were 1.10 mmol/L (97 mg/dL). Results of urinalysis were normal. His sweat chloride level was 26 mmol/L. Findings from abdominal ultrasonography showed significant fluid containing debris and strands displacing the intestinal loops posteriorly. Abdominal paracentesis revealed hazy yellow fluid with analysis indicating a leukocyte level of $2.2 \times 10^9/L$ with 2% polymorphonuclear forms and 95% lymphocytes; glucose, 5.2 mmol/L (94 mg/dL); total protein, 41 g/L; albumin, 30 g/L; cholesterol, 1.5 mmol/L (58 mg/dL); and triglycerides, 0.4 mmol/L (35 mg/dL). No malignant cells were present, and no organisms or acid fast bacilli were present on staining. Findings from bacterial and fungal cultures of the fluid were sterile. Results from Doppler ultrasonography of the portal vein and an upper and small-bowel radiographic examination were normal. An abdominal tap was repeated after a fatty meal, and fluid analysis showed a leukocyte count of $1.6 \times 10^9/L$ with 100% lymphocytes; protein, 44 g/L; albumin, 30 g/L; and triglycerides, 0.26 mmol/L (23 mg/dL). Fluid urea and creatinine levels were less than their serum concentrations. Abdominal computed tomography was performed (**Figure**).

From the Al-Hasa Specialty Services Division, Saudi Aramco-Al-Hasa Health Center, Saudi Aramco Medical Services Organization, Mubarratz, Kingdom of Saudi Arabia. Dr Narchi is currently with the Paediatric Department, Sandwell General Hospital, West Bromwich, England.



Denouement and Discussion

Omental Cyst Presenting as Pseudoascites

Abdominal computed tomographic scan with oral and intravenous contrast showing fluid displacing posteriorly the centrally located and clumped intestinal loops.

Laparoscopy was performed and revealed a massive omental cyst containing about 200 mL of blood-tinged fluid occupying the entire peritoneal cavity. A cystectomy was performed, and findings from histopathologic examination showed an intraperitoneal lymphatic cyst.

In ascites there is abdominal distension, pouting of the umbilicus, scrotal swelling, and bulging flanks with fluctuation, shifting dullness, and a fluid wave on palpation. The chemical and hematological characteristics of ascitic fluid help in establishing an etiological diagnosis (portal hypertension, hypoalbuminemia, infection, chyle, and urinary or gastrointestinal tract leaks). Atypical of ascites in the patient we describe was the absence of flank bulging, the posterior displacement of intestinal loops on findings from abdominal ultrasonography and computed tomography, and the hazy yellow appearance of the fluid obtained by paracentesis in the absence of clinical or biochemical evidence of liver disease.

Mesenteric cysts, with sizes varying from a few centimeters to more than 30 cm in diameter, may occur in the ileal or small bowel mesentery, the root of the mesentery with retroperitoneal extension, the transverse mesocolon, or the gastrocolic ligament. When they are located anterior to the intestine, they are called omental cysts. Unilocular or multilocular, they often contain chylous fluid. A thin wall, internal septations, and an endothelial lining are characteristic of the cysts.¹ They are caused either by gradual enlargement of lymphatic spaces because of obstruction of the lymphatic channels or by congenitally atopic lymphatic tissue that does not communicate with the vascular system. Approximately one third of patients with these lesions are children.

The rarity of these lesions and lack of characteristic clinical features may present diagnostic difficulties. Most cases are asymptomatic. The clinical presentation relates to size, location, and complications, such as bowel obstruction, perforation, peritonitis, volvulus, or malignant degeneration. Presenting symptoms include abdominal distension, pain, and vomiting, mimicking appendicitis or an acute abdomen.²⁻⁴ A painless, asymptomatic, compressible, and freely movable abdominal mass may be the mode of presentation. Mesenteric cysts may cause complete or partial intestinal obstruction or torsion of the small bowel.^{5,6} A hemorrhagic or ruptured mesenteric cyst following trauma⁷⁻⁹ is an abdominal emergency.

As reported in this case, giant mesenteric cysts mimic ascites with abdominal distension, shifting dullness, and the presence of a fluid wave, but a useful distinguishing clinical characteristic is the absence of flank bulging.¹⁰⁻¹² Ultrasonography is the diagnostic method of choice and demonstrates the appearance of well-defined, anechoic masses,

loculations, or septated ascites. An omental cyst appears as a well-outlined, sonolucent, transonic abdominal mass. Computed tomography is reserved for atypical cases.

Complete cyst resection is the treatment of choice. Partial bowel resection is required in some cases. Laparoscopic surgery is performed in selected cases when the preoperative diagnosis is certain. Mesenteric cysts should be considered in the differential diagnosis of abdominal distension, mass or pain, acute abdomen, ascites, or bowel obstruction.

Accepted for publication January 24, 1999.

Reprints: Hassib Narchi, MD, FRCP, FRCPC, Paediatric Department, Sandwell General Hospital, Lyndon, West Bromwich, B71 4HJ, West Midlands, England (e-mail: hassibnarchi@hotmail.com).

REFERENCES

1. Vanek VW, Phillips AK. Retroperitoneal, mesenteric, and omental cysts. *Arch Surg.* 1984;119:838-842.
2. Egozi EI, Ricketts PR. Mesenteric and omental cysts in children. *Am Surg.* 1997;63:287-290.
3. Chung MA, Brandt ML, St-Vil D, Yazbeck S. Mesenteric cysts in children. *J Pediatr Surg.* 1991;26:1306-1308.
4. Bliss DPJ, Coffin CM, Bower RJ, Stockmann PT, Temberg JL. Mesenteric cysts in children. *Surgery.* 1994;115:571-577.
5. Wong SW, Gardner V. Sudden death in children due to mesenteric defect and mesenteric cyst. *Am J Forensic Med Pathol.* 1992;13:214-216.
6. Namasivayam J, Ziervogel MA, Hollman AS. Case report: volvulus of a mesenteric cyst: an unusual complication diagnosed by CT. *Clin Radiol.* 1992;46:211-212.
7. Ulman I, Herek O, Ozok G, Avanoğlu A, Erdener A. Traumatic rupture of mesenteric cyst: a life-threatening complication of a rare lesion. *Eur J Pediatr Surg.* 1995;5:238-239.
8. Porras-Ramirez G, Hernandez-Herrera MH. Hemorrhage into mesenteric cyst following trauma as a cause of acute abdomen. *J Pediatr Surg.* 1991;26:847-848.
9. Klin B, Lotan G, Efrati Y, Vinograd I. Giant omental cyst in children presenting as pseudoascites. *Surg Laparosc Endosc.* 1997;7:291-293.
10. Gyves-Ray K, Hernandez RJ, Hillemeier AC. Pseudoascites: unusual presentation of omental cyst. *Pediatr Radiol.* 1990;20:560-561.
11. Gordon MJ, Sumner TE. Abdominal ultrasonography in a mesenteric cyst presenting as ascites. *Gastroenterology.* 1975;69:761-764.
12. Chou YH, Tiu CM, Lui WY, Chang T. Mesenteric and omental cysts: an ultrasonographic and clinical study of 15 patients. *Gastrointest Radiol.* 1991;16:311-314.

Submissions

The Editors welcome contributions to *Pathological Case of the Month*, *Picture of the Month*, and *Radiological Case of the Month*. Those who wish to contribute should send their manuscripts to Dr Gilbert-Barness (*Pathological Case of the Month*), Department of Pathology, Tampa General Hospital, University of South Florida, Davis Island, Tampa, FL 33606; Dr Tunnessen (*Picture of the Month*), The American Board of Pediatrics, 111 Silver Cedar Ct, Chapel Hill, NC 27514-1651; or Dr Wood (*Radiological Case of the Month*), KAM 211, USC-HSC, 1975 Zonal Ave, Los Angeles, CA 90089-9024. Articles and photographs accepted for publication will bear the contributor's name. There is no charge for reproduction and printing of color illustrations.