SECTION EDITOR: WALTER W. TUNNESSEN, JR, MD

Picture of the Month

Debra L. Bogen, MD; Robin P. Gehris, MD; Mark F. Bellinger, MD

A MASS was discovered protruding between the labia minora of a 12-hour-old newborn infant. The mass was noticeable when the infant cried. She had passed meconium and had voided 3 times. Findings from the remainder of the physical examination were unremarkable. The mass was soft, tense, and seemed nontender (**Figure 1**). It was pale and translucent in appearance and increased in size as she cried. No urethral or vaginal openings could be identified. **Figures 2**, **3**, **4**, and **5** show other interlabial masses to consider in the differential diagnosis of this lesion.

From the Divisions of General Academic Pediatrics (Dr Bogen), Pediatric Residency (Dr Gehris), and Urologic Surgery (Dr Bellinger), Children's Hospital of Pittsburgh, Pittsburgh, Pa.

Figure 1.

Figure 2.

Figure 3.

Figure 4.

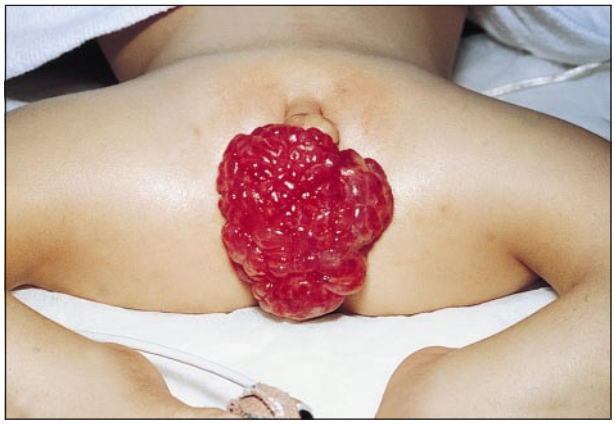

Figure 5.

©2000 American Medical Association. All rights reserved.
Downloaded From: http://archpedi.jamanetwork.com/ on 05/22/2015

Denouement and Discussion

Imperforate Hymen With Hydrocolpos

Figure 1. *Imperforate hymen with hydrocolpos.*

Figure 2. *Prolapsed urethra.*

Figure 3. *Ectopic ureterocele.*

Figure 4. *Paraurethral cyst.*

Figure 5. *Rhabdomyosarcoma of the vagina.*

The differential diagnosis of an interlabial mass in a newborn infant or a young girl includes hydro(metro)colpos, prolapsed urethra, prolapsed ureterocele, paraurethral cyst, and rhabdomyosarcoma of the vagina.[1,2] Although it may be difficult to distinguish between these lesions, evaluation of the relationship of the urethral opening to the mass and the quality of the mass are key to the proper diagnosis. In our patient, findings from pelvic ultrasonographic examination disclosed a large, fluid-filled vagina secondary to an imperforate hymen. Hymenotomy resulted in drainage of 500 mL of milky fluid.

Hydro(metro)colpos is the distension of the vagina and uterus by accumulated mucus and/or blood secreted by the uterine and cervical glands stimulated in utero by maternal estrogen or withdrawal of estrogen after birth. Imperforate hymen, transverse vaginal septum, or vaginal atresia may be responsible for this lesion. Accumulated secretions behind an intact hymen or a low transverse vaginal septum may produce the interlabial mass. The mass may compress the adjacent bladder, ureters, bowel, or pelvic veins, resulting in urinary retention, constipation, or edema of the lower extremities. Whereas an imperforate hymen and low septum rarely are associated with other congenital anomalies, a mid or high septum and vaginal atresia are almost always associated with other gastrointestinal or genitourinary anomalies.[3] Half of all cases of hydrocolpos are identified in the newborn period, and the other half are diagnosed during adolescence.[4]

Prolapsed urethra most commonly occurs in black, premenarcheal girls. The mass is smooth, round, bright red or cyanotic, and completely encircles the urethral meatus. The vaginal opening should be identified posterior to the mass. The mucosa of the prolapsed urethra is friable, resulting in a presenting complaint of spotting, vaginal bleeding, or hematuria.[5] Urine can be obtained by passing a catheter through the central lumen. Congenital abnormalities are not associated with this lesion.

Ectopic ureterocele is a congenital cystic dilatation of the terminal ureter, usually associated with the upper portion of a duplicated collecting system. Most ureteroceles remain fixed, but they may prolapse into or through the urethra during voiding. The condition is seen almost exclusively in white girls and may present as sudden, intermittent, or chronic urinary retention. A prolapsed ureterocele appears as a smooth, round, red to purplish-blue, depending on the duration of prolapse, interlabial mass. The urethral opening may not be easily identifiable because it surrounds the mass. If urination occurs, urine will flow around the mass.

Paraurethral cyst is a less common cause of interlabial masses. The cysts are epithelial lined and thought to arise from obstruction or cystic degeneration of remnants of the urogenital sinus, mullerian ducts, or mesonephric ducts. The mass displaces the urethral meatus laterally. The vaginal opening should be visible midline and posterior to the mass. Aspiration of the cyst yields a small quantity of milky fluid.

Rhabdomyosarcoma of the vagina (sarcoma botryoides) is the most common primary malignant tumor of the vagina, uterus, and bladder in the first 5 years of life. It may be differentiated from the other disorders by its grape-like clusters of pearly gray masses that may be separate from the urethral meatus or protrude from it.

Careful, routine exmination of the genitalia of newborns will reinforce the range of normal genital findings and increase the likelihood of identifying less common anomalies. An interlabial mass is an unusual finding. Familiarity with the differential diagnosis of these masses is necessary to determine the need for radiologic evaluation and referral to pediatric surgeons or urologists.

Accepted for publication February 18, 1999.

Reprints: Debra L. Bogen, MD, Children's Hospital of Pittsburgh, 3705 Fifth Ave, Pittsburgh, PA 15213-2583.

REFERENCES

1. Nussbaum AR, Lebowitz RL. Interlabial masses in little girls: review of imaging and recommendations. *Am J Radiol.* 1983;141:65-71.
2. Merguerian PA, McLorie GA. Disorders of the female genitalia. In: Kelalis PP, King LR, Belman AB, eds. *Clinical Pediatric Urology, 3rd ed.* Philadelphia, Pa: WB Saunders Co; 1992:1098-1101.
3. Tran ATB, Arensman RM, Falterman KW. Diagnosis and management of hydrohematometrocolpos syndromes. *AJDC.* 1987;141:632-634.
4. Spencer R, Levy D. Hydrometrocolpos: report of three cases and review of the literature. *Ann Surg.* 1962;155:558-571.
5. Anveden-Hertzberg L, Gauderer MWL, Elder JS. Urethral prolapse: an often misdiagnosed cause of urogenital bleeding in girls. *Pediatr Emerg Care.* 1995;11:212-214.

©2000 American Medical Association. All rights reserved.
Downloaded From: http://archpedi.jamanetwork.com/ on 05/22/2015