SECTION EDITOR: ENID GILBERT-BARNESS, MD

Pathological Case of the Month

Sonya Rae Arnold, MD; Charmaine Cameron Baker, MD; Enid Gilbert-Barness, MD

A 15-YEAR-OLD BOY was referred with progressive left lower extremity weakness, severe lower back pain, and an abnormal gait for 2 months. He underwent a double herniorrhaphy at age 6 months and was diagnosed with kyphoscoliosis at age 13 years. On physical examination, he weighed 53 kg and was 180 cm tall. There was circumduction of the left lower extremity. The left thigh circumference was 2 cm smaller than the right, and the left gluteal muscles were atrophic. There was decreased pain sensation, and muscle tone was increased; however, motor strength was decreased, particularly in the hip flexors. Babinski signs were present bilaterally.

Magnetic resonance imaging (MRI) revealed multiple intradural, intramedullary, and extramedullary masses throughout the spinal canal (**Figure 1**); the nerve roots of the cauda equina were also involved. Imaging studies of the brain showed bilateral masses involving the seventh and eighth cranial nerves (**Figure 2**). The patient underwent partial excision of the mass in the cauda equina; microscopic sections are shown (**Figure 3** and **Figure 4**).

From the Departments of Pathology (Drs Arnold and Gilbert-Barness) and Pediatrics (Dr Cameron Baker), Tampa General Hospital, Tampa, Fla. Dr Arnold is now with the Department of Pathology, University of Miami School of Medicine, Miami, Fla.

Figure 1.

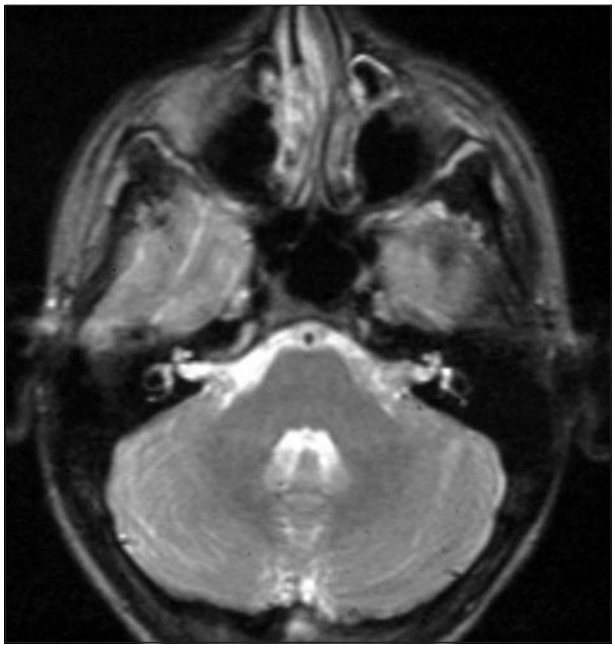

Figure 2.

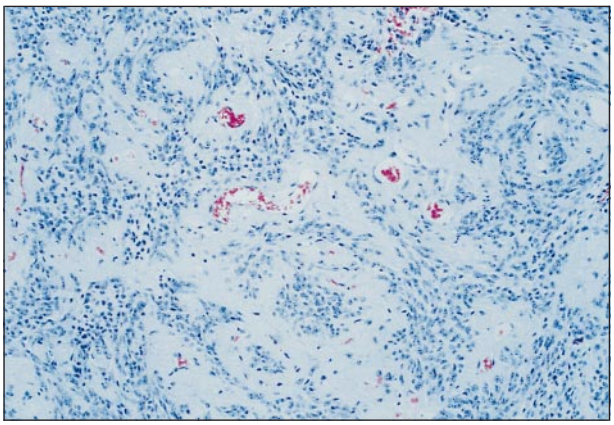

Figure 3.

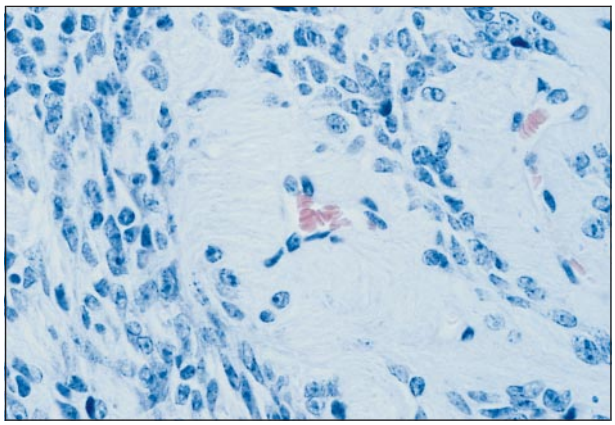

Figure 4.

©2000 American Medical Association. All rights reserved.
Downloaded From: http://archpedi.jamanetwork.com/ on 05/24/2016

Diagnosis and Discussion

Neurofibromatosis 2 With Bilateral Vestibular Schwannomas and Spinal Cord Ependymoma

Figure 1. *A large mass involving the lower thoracic and upper lumbar spinal cord segments and multiple masses involving nerve roots of the cauda equina.*

Figure 2. *Cranial magnetic resonance image showing bilateral masses. involving the seventh and eighth cranial nerves.*

Figure 3. *Spinal cord ependymoma consisting of a cellular neoplasm composed of small blue cells alternating with acellular fibrillary areas (perivascular pseudorosettes) surrounding blood vessels (hematoxylin-eosin, original magnification ×100).*

Figure 4. *High-power view of ependymoma with perivascular pseudorosettes (hematoxylin-eosin, original magnification ×400).*

The neurofibromatoses (NF) comprise a group of disorders characterized by an autosomal dominant genetic predisposition to the development of various neural crest cell neoplasms. Although any organ system can be involved, the tumors typically affect the skin and nervous system. Currently, 8 subtypes are recognized.[1] The best-described variants, NF 1 and 2, were once designated peripheral and central NF, respectively. However, use of those terms is inappropriate because either condition can involve the central or peripheral nervous systems.[2] Molecular tests have confirmed that they are genetically distinct conditions.

Neurofibromatosis 1 occurs in approximately 1:3000 to 1:4000 individuals.[1,3,4] It localizes to a genetic defect on chromosome 17q.[3,4] Café au lait spots, freckling of the axillary and inguinal regions, peripheral neurofibromas, and Lisch nodules are the cardinal features.[3,5,6] Plexiform neurofibromas and central nervous system tumors such as optic nerve gliomas are common sequelae.[1] Although NF 1 is autosomal dominant, 50% of cases represent new mutations.[3,5,6]

With an estimated incidence of 1:40 000,[1,3,4] NF 2 is seen less frequently. The NF 2 gene has been localized to chromosome 22q12.[7] Studies suggest that the NF 2 gene functions as a tumor suppressor.[8] Most individuals with NF 2 develop the hallmark feature, bilateral vestibular schwannomas, by the second or third decade.[2-4] They typically have progressive and unilateral hearing loss; many initially notice this when using the telephone.[2,4] Tinnitus and vertigo are other common symptoms.[2] Facial weakness, sensory changes, ataxia, headaches, and diplopia may also be present.[4] Approximately 30% of patients with NF 2 have nonvestibular schwannomas, and 50% develop intracranial meningiomas.[3] Spinal cord tumors, usually ependymomas, and meningiomas are common,[3] affecting up to 89% of patients in one series.[9] More than half of patients with NF 2 have peripheral nerve tumors, usually schwannomas, appearing as plaques, nodules, or cutaneous neurofibromas and resembling those seen in NF 1.[5] Most patients with NF 2 have ocular lesions. Cataracts, retinal hamartomas, epiretinal membranes, and optic disc gliomas may also develop.[5] Café au lait spots are not nearly as frequent as in NF 1 cases.[5] The diagnosis of NF 2 should be considered in any child with a posterior cataract, peripheral nerve neoplasms,[3] or multiple central nervous system tumors, particularly in the absence of café au lait spots or Lisch nodules.[3,10]

Diagnostic criteria[11] include (1) bilateral vestibular schwannomas, observed by MRI; and (2) a first-degree relative with NF 2 and either a unilateral vestibular schwannoma or any 2 of the following: meningioma, glioma, schwannoma, juvenile subcapsular lenticular opacities/juvenile cortical cataracts.[6] Family members are at risk. The condition is autosomal dominant, with a 50% risk of penetrance. The NF 2 gene can be identified by direct molecular genetic testing.[5,6,10] First-degree relatives require a thorough ophthalmologic and neurologic examination. Newly diagnosed patients and at-risk family members must be counseled about balance disturbances and should exercise caution when swimming, diving,[2] or climbing at high altitudes.[6]

Adequate treatment of NF 2 requires a strong collaborative effort between multiple specialists. Newly diagnosed individuals should undergo full MRI (with and without gadolinium) of the head and spinal cord. Thorough neurologic, skin, and ophthalmologic examinations are requisite.[4] Clinical workup should also include brainstem auditory-evoked responses and audiometry testing for hearing dysfunction.[4,6] Treatment modalities can include observation, surgery, and radiation. With resection of vestibular tumors, there is a risk of permanent sequelae. Optimally, a vestibular schwannoma can be excised with minimum morbidity and mortality,[2] particularly small tumors that are confined to the internal auditory canal. Spinal cord tumors should be closely followed by MRI. Spinal cord meningiomas and nerve sheath tumors tend to be slow growing and multiple[2,3]; they may reach a large size before becoming clinically evident.[3] Pollack and Mulvihill[3] recommend resection of tumors that compress the spinal cord. Generally, most glial hamartomas and low-grade gliomas, both common in NF 2, are not aggressive.[2]

Accepted for publication April 30, 2000.

Reprints: Sonya Arnold, MD, Box 1289, Tampa General Hospital, Tampa, FL 33601.

REFERENCES

1. Riccardi VM. *Neurofibromatosis: Phenotype, Natural History, and Pathogenesis.* 2nd ed. Baltimore, Md: The Johns Hopkins University Press; 1992.
2. Martuza RL, Eldridge R. Neurofibromatosis 2 (bilateral acoustic neurofibromatosis). *N Engl J Med.* 1988;318:684-688.
3. Pollack IF, Mulvihill JJ. Neurofibromatosis 1 and 2. *Brain Pathol.* 1997;7:823-836.
4. Zoghbi HY, Ballabio A. Neurofibromatosis 2. In: Scriver CR, Beaudet AL, Sly WS, Valle D, eds. *The Metabolic and Molecular Basis of Inherited Disease.* 7th ed. New York, NY: McGraw-Hill, Inc; 1995:4593-4597.
5. Huson SM, Rosser EM. The phakomatoses. In: Rimoin DL, Connor JM, Pyeritz RE, eds. *Emery and Rimoin's Principles and Practice of Medical Genetics.* 3rd ed. New York, NY: Churchhill Livingstone; 1996:2269-2281.
6. Gutmann DH, Aylsworth A, Carey JC, et al. The diagnostic evaluation and multidisciplinary management of neurofibromatosis 1 and neurofibromatosis 2. *JAMA.* 1997;278:51-57.
7. Rouleau GA, Merel P, Lutchman M et al. Alteration in a new gene encoding a putative membrane organizing protein causes a neurofibromatosis type 2. *Nature.* 1993;363:515-521.
8. Seizinger BR, Rouleau G, Ozelius LJ, et al. Common pathogenetic mechanism for three tumor types in bilateral acoustic neurofibromatosis. *Science.* 1987;236:317-319.
9. Mautner VF, Tatagiba M, Lindenau M, et al. Spinal tumors in patients with neurofibromatosis 2. *AJR Am J Roentgenol.* 1995; 165:951-955.
10. Mautner VF, Tatagiba M, Guthoff R, et al. Neurofibromatosis in the pediatric age group. *Neurosurgery.* 1993;33:92-96.
11. National Institutes of Health Conference. Neurofibromatosis: Conference Statement. *Arch Neurol.* 1988:45:575-578.

©2000 American Medical Association. All rights reserved.
Downloaded From: http://archpedi.jamanetwork.com/ on 05/24/2016