

SECTION EDITOR: ENID GILBERT-BARNES, MD

## Pathological Case of the Month

Christopher J. Magryta, MD; Randolph Hennigar, MD; Mark Weatherly, MD

**A** 15-YEAR-OLD WHITE BOY was diagnosed as having cystic fibrosis (CF) at age 4 years after symptoms of projectile vomiting, bulky stools, and anemia. Of 32 alleles tested, his genotype is N1303K/unidentified allele. He had multiple hospital admissions through age 2 years and only 4 until 1991, age 7 years. In 1994, he had a biliary tract obstruction requiring endoscopic intervention. In February 1991, he was diagnosed as having diabetes mellitus (DM) glucose intolerance. Subsequently, a therapeutic regimen of glipizide and a diet with no concentrated sweets was begun. Later that year, during a hospitalization, he had sustained elevated serum glucose levels while receiving prednisone. His hemoglobin A<sub>1c</sub> level was 6.1 mg/dL. Urine protein was monitored regularly from 1991 through 1994, and traces began to appear in June 1992

but did not reach high levels until 1994. At hospital admission, he was receiving glipizide by mouth, 5 mg every morning and 10 mg every evening. He had a history of non-compliance with daily glucose monitoring, and many spot glucose measurements were taken, measuring in the 16.7-mmol/L (300-mg/dL) range. After urine protein levels reached 1528 mg/24 h in August 1994, a renal biopsy was performed. Hemoglobin A<sub>1c</sub> levels were 12.3 in February 1994 and 8.2 in August 1994. The patient never had clinical symptoms of glomerulonephritis (**Figures 1, 2, 3, 4, and 5**).

From the Department of Pediatrics, Emory University School of Medicine, Atlanta, Ga. Dr Magryta is now with the Salisbury Children's Clinic, Salisbury, NC, and Dr Weatherly is now with the Nemours Children's Foundation, Orlando, Fla.

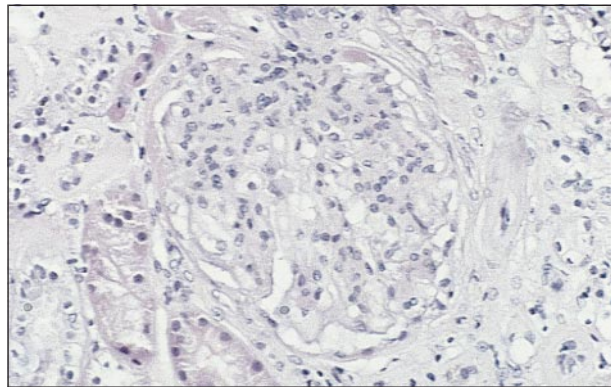


Figure 1.

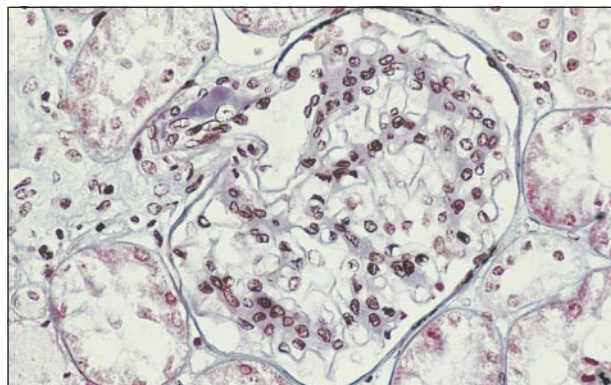


Figure 2.

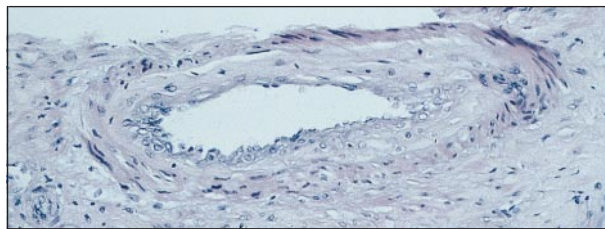


Figure 3.

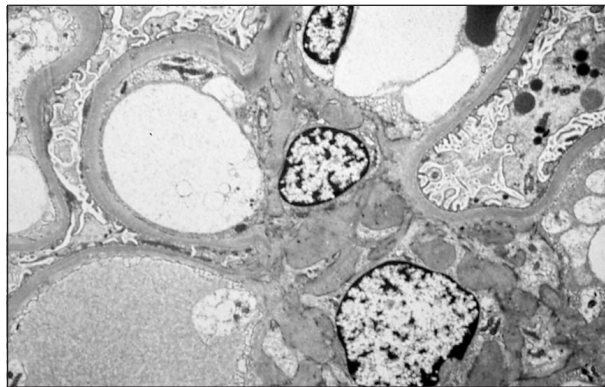

Figure 4.

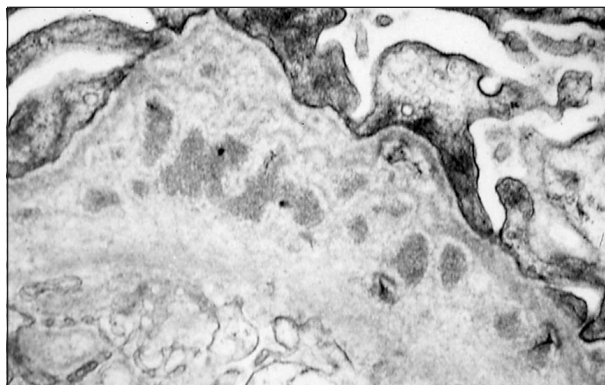


Figure 5.

# Diagnosis and Discussion

## Diabetic Nephropathy in Cystic Fibrosis

**Figure 1.** Microscopic section of the renal biopsy specimen showing mesangial hypercellularity and matrix increase. Glomerular arterioles exhibit hyaline change (hematoxylin-eosin, original magnification  $\times 200$ .)

**Figure 2.** Microscopic section showing increased mesangial matrix (Masson trichrome, original magnification  $\times 200$ .)

**Figure 3.** Microscopic section showing mild atherosclerosis (hematoxylin-eosin, original magnification  $\times 220$ .)

**Figure 4.** Electron photomicrograph demonstrating mildly thickened glomerular basement membranes and increased mesangial matrix (uranyl acetate-lead citrate, original magnification  $\times 15\,000$ .)

**Figure 5.** Electron photomicrograph showing rare dense deposits in glomerular capillary loops (uranyl acetate-lead citrate, original magnification  $\times 35\,000$ .)

The clinical history of DM implied that the glomerular, tubulointerstitial, and vascular scarring in this young patient was owing in part to early progression of diabetic nephropathy. A superimposed, mediated immune complex glomerulonephritis characterized by mesangial proliferation and rare immune deposits was present in the glomerular basement membranes (GBMs) and mesangia. The mesangial hypercellularity and distribution of sparse immune deposits, some of which were rarefied, suggested resolving postinfectious glomerulonephritis. This interpretation derives support from Abramowsky and Swinehart,<sup>1</sup> who attributed similar mesangiopathic lesions to a postinfectious process in their study of nephropathy in young patients with CF.

Diabetes mellitus nephropathy is characterized pathologically by histologic changes that occur in the GBMs, mesangial matrix, and vasculature. The GBM is thickened by a homogeneous hyaline structure that is periodic acid-Schiff positive. Mild proliferation of mesangial cells with notable matrix increase when combined with thickened GBM leads to diffuse glomerulosclerosis. The pathogenesis of the disease is hypothesized to be due to 4 factors: (1) metabolic defect of increased glucose or decreased insulin with direct effects; (2) increased type IV collagen and fibronectin in the GBM with decreased proteoglycan; (3) new enzymatic glycosylation of proteins, ie, the GBM collagen; and (4) increased glomerular filtration rate and glomerular hypertrophy.<sup>2</sup>

The increased life expectancy of patients with CF observed over the last 25 years has been associated with an increased prevalence of DM in the population with CF.<sup>3</sup> Patients with CF with long-standing DM are at increased risk for developing microangiopathic effects on the eyes, kidneys, and nervous system much like patients with DM without CF.

Reports from 6 studies<sup>4-9</sup> of patients with CF found that 4.9% to 14.7% of patients with CF were clinically diagnosed as having DM. The CF genotype also seems

to play a major role in the development of DM in patients with CF. Rosenecker et al<sup>4</sup> found that 75% and 19% of 39 patients with CF and DM, respectively, had homozygous and heterozygous  $\Delta F508$  gene deletions. Age of onset tends to be in the second decade of life, but has been reported as early as age 2 years.<sup>10</sup> The cause of diabetes in patients with CF has been attributed to decreased beta-islet cell number and reduced insulin levels and C-peptide activity.<sup>11</sup> Insulin resistance has been noted to influence glucose tolerance in CF.<sup>12</sup> Pancreatic fibrosis along with these other pancreatic changes are believed to play a major role in the incidence of DM in patients with CF.

Diabetic microangiopathy, as in our patient, is becoming more important as longevity increases for patients with CF. Sullivan and Denning<sup>11</sup> studied 19 patients with CF and DM from 1978 through 1987 and found that 4 (21%) had microangiopathic complications secondary to DM. This development of multisystem microvascular disease in 3 patients after having DM for 10 years is similar to the pattern seen in patients with DM without CF.<sup>11</sup> Our patient's presentation was atypical and accelerated compared with the usual documented progression of complications from DM. As with this patient, the clinician needs to be increasingly alert for presentations of microangiopathic changes of DM in patients with CF who have DM.

Accepted for publication April 30, 1999.

Reprints: Mark Weatherly, MD, Nemours Children's Foundation, 83 W Columbia St, Orlando, FL 32806.

## REFERENCES

1. Abramowsky R, Swinehart GL. The nephropathy of cystic fibrosis: a model of chronic nephrotoxicity. *Hum Pathol.* 1982;13:934-939.
2. Cotran RS, Kumar V, Robbins SL. *Robbin's Pathologic Basis of Disease.* Philadelphia, Pa: WB Saunders Co; 1994:961-963.
3. Rodman HM, Doershuk CF, Roland JM. The interaction of two diseases: diabetes mellitus and cystic fibrosis. *Medicine (Baltimore).* 1986;65:389-397.
4. Rosenecker J, Eichler I, Kuhn L, et al. Genetic determination of diabetes mellitus in patients with cystic fibrosis. *J Pediatr.* 1995;127:441-443.
5. Reisman J, Corey M, Canny G, et al. Diabetes mellitus in patients with cystic fibrosis: effect on survival. *Pediatrics.* 1990;86:374-377.
6. Finkelstein SM, Wielinski CL, Elliot GR, et al. Diabetes mellitus associated with cystic fibrosis. *J Pediatr.* 1988;112:373-377.
7. Kreuger LJ, Lerner A, Katz SM, et al. Cystic fibrosis and diabetes mellitus: interactive or idiopathic? *J Pediatr Gastroenterol Nutr.* 1991;13:209-219.
8. Hayes FJ, O'Brien A, O'Brien C, et al. Diabetes mellitus in an adult cystic fibrosis population. *Ir Med J.* 1994;87:59-60.
9. Lannig S, Thorsteinsson B, Lund-Anderson C, et al. Diabetes mellitus in Danish cystic fibrosis patients: prevalence and late diabetic complications. *Acta Paediatr.* 1994;83:72-77.
10. Pfeifer T. Diabetes in cystic fibrosis. *Clin Pediatr.* November 1992:682-687.
11. Sullivan MM, Denning CR. Diabetic microangiopathy in patients with cystic fibrosis. *Pediatrics.* 1989;84:642-647.
12. Culler FL, McKean LP, Buchanan CN, et al. Glipizide treatment of patients with cystic fibrosis and impaired glucose tolerance. *J Pediatr Gastroenterol Nutr.* 1994;18:375-378.