SECTION EDITOR: ENID GILBERT-BARNESS, MD

Pathological Case of the Month

John J. Buchino, MD; Mary E. Fallat, MD; Vicki L. Montgomery, MD

A 10-YEAR-OLD GIRL was referred to us for surgical evaluation of an asymptomatic cystic nodule in the upper midline neck that had been present for 2 months. The nodule was noticed by her mother when the child was looking at the ceiling. The child was otherwise healthy with no signs or symptoms of thyroid disease. On examination, the nodule measured approximately 1.5 cm in diameter and was closely associated with the hyoid bone. The nodule was not very mobile to manipulation, but moved freely with tongue motion. The thyroid gland was palpably normal and there was no cervical adenopathy. Thyroid function test results were normal.

Presumptive diagnosis was a thyroglossal duct cyst. A standard Sistrunk procedure was done with excision of the cyst in continuity with the mid portion of the hyoid bone.[1] Postoperative healing was uneventful.

Microscopic examination of the mass is depicted in **Figures 1**, **2**, **3**, and **4**.

From the Departments of Pediatrics (Drs Buchino and Montgomery), Pathology (Dr Buchino), and Surgery (Dr Fallat), University of Louisville School of Medicine, Louisville, Ky; and the Department of Pathology (Dr Buchino), Kosair Children's Hospital, Louisville.

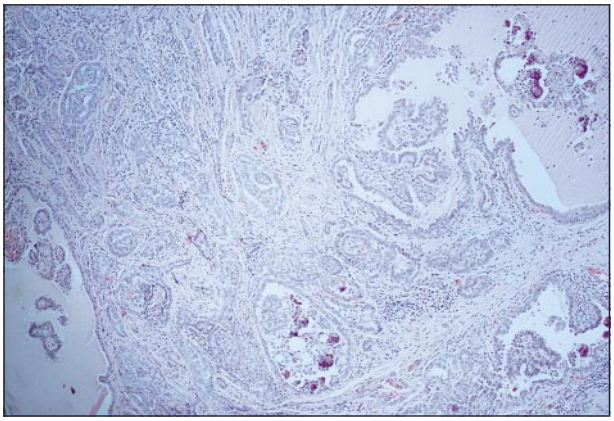

Figure 1.

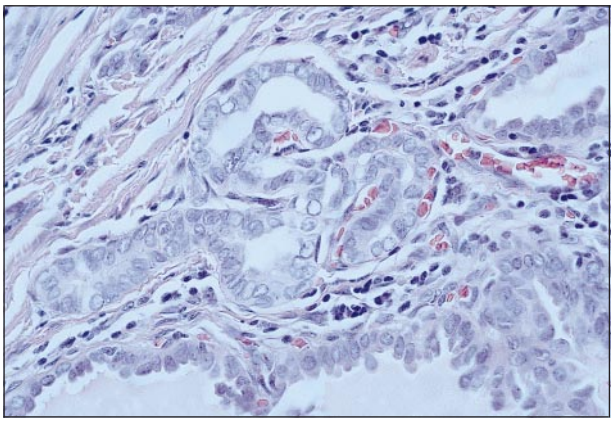

Figure 2.

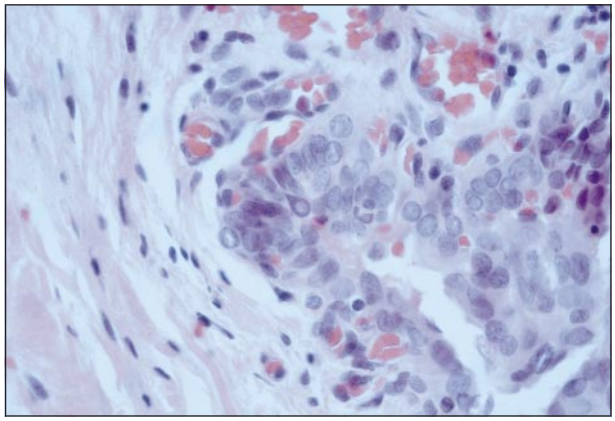

Figure 3.

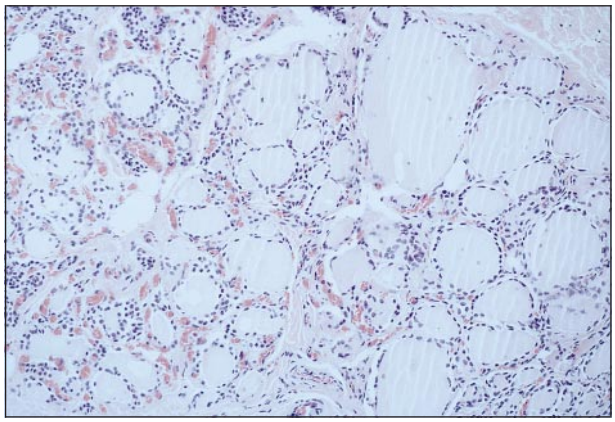

Figure 4.

©1999 American Medical Association. All rights reserved.
Downloaded From: http://archpedi.jamanetwork.com/ on 07/22/2014

Diagnosis and Discussion

Papillary Carcinoma of the Thyroid in a Thyroglossal Duct Remnant

Figure 1. *Low-power view of surgical specimen revealing tumor with papillary projections into cystic spaces and scattered calcification (hematoxylin-eosin, original magnification ×60).*

Figure 2. *Papillary projections surfaced by epithelial cells with nuclear folding and optically clear "Orphan Annie" nuclei (hematoxylin-eosin, original magnification ×400).*

Figure 3. *An epithelial cell with an intranuclear pseudoinclusion is present in the center of the field (hematoxylin-eosin, original magnification ×500).*

Figure 4. *Normal thyroid tissue adjacent to tumor (hematoxylin-eosin, original magnification ×250).*

The thyroid gland develops from the floor of the pharynx between pharyngeal arches 1 and 2. It is anchored to the pharynx by a stalk known as the thyroglossal duct (TGD). As the thyroid gland descends to its normal position, it remains connected to the tongue by the TGD, which may pass around or through the hyoid bone. After embryogenesis the TGD usually disappears, but remnants may give rise to a TGD cyst or a fistula.

Thyroglossal duct cysts are the most common midline neck mass found in children. There is no sex predilection and they are typically diagnosed by age 10 years. Because of the likelihood of infection or rupture, surgical excision is the treatment of choice. The central portion of the hyoid bone as well as an en bloc resection of the soft tissue surrounding the cyst (Sistrunk procedure) is recommended to prevent recurrence.[2] Microscopic examination reveals thyroid tissue remnants adjacent to the cyst in less than a third of the cases.

Carcinoma arising in a TGD is rare, with only approximately 200 reported cases and an estimated incidence of less than 1%. Most cases have occurred in adults and the overwhelming majority are papillary carcinoma. While the carcinoma may evolve from ductal epithelium, approximately 90% of cases originate from thyroid remnants.[3] There seem to be no predisposing factors. Typically, neither clinical history nor physical examination leads to the preoperative diagnosis.

Thyroid papillary carcinoma has characteristic features that were readily found in this case. In addition to the numerous papillary protrusions, psammomatous calcifications are frequently scattered throughout the tumor. The cells surfacing the papillae exhibit nuclear folds and often have optically clear or "Orphan Annie" nuclei. Nuclear pseudoinclusions are also found, which are actually cytoplasmic invaginations.

While carcinoma of the thyroid gland is not common in children, when it does occur it is usually papillary. Papillary carcinoma is a very slow-growing neoplasm with an excellent cure rate. When it occurs in the thyroid, the treatment of choice is subtotal thyroidectomy. However, the best treatment of TGD papillary carcinoma is unclear. This is because between 11% and 33% of the cases reported have also had a second focus of tumor in the thyroid gland.[3,4] These second foci are often not detectable by either physical examination or nucleotide scans. Weiss and Orlich[3] believed that because papillary thyroid carcinoma has a prolonged course, in the absence of objective suspicion of a thyroid mass, only long-term follow-up is warranted. In contrast, Heshmati et al[4] recommended thyroidectomy on all patients with TGD carcinoma. However, the youngest patient in their series was aged 17 years and, therefore, they allow for a different approach in younger children. Given the excellent cure rate for papillary thyroid carcinoma, further treatment for this child should be limited to regular physical examinations and periodic imaging.

Accepted for publication February 19, 1999.

Reprints: John J. Buchino, MD, Kosair Children's Hospital, PO Box 35070, Louisville, KY 40207.

REFERENCES

1. Sistrunk WE. Technique of removal of cysts and sinuses of the thyroglossal duct. *Surg Gynecol Obstet.* 1928;46:109-112.
2. Bennett KG, Organ CH, Williams GR. Is treatment for thyroglossal duct cysts too extensive? *Am J Surg.* 1986;152:602-605.
3. Weiss SD, Orlich CC. Primary papillary carcinoma of a thyroglossal duct cyst: report of a case and literature review. *Br J Surg.* 1991;78:87-89.
4. Heshmati HM, Fatourechi V, Van Heerden JA, et al. Thyroglossal duct carcinoma: report of 12 cases. *Mayo Clin Proc.* 1997;72:315-319.

Submissions

The Editors welcome contributions to Pathological Case of the Month, Picture of the Month, *and* Radiological Case of the Month. *Those who wish to contribute should send their manuscripts to Dr Gilbert-Barness* (Pathological Case of the Month), *Department of Pathology, Tampa General Hospital, University of South Florida, Davis Island, Tampa, FL 33606; Dr Tunnessen* (Picture of the Month), *The American Board of Pediatrics, 111 Silver Cedar Ct, Chapel Hill, NC 27514-1651; or Dr Wood* (Radiological Case of the Month), *KAM 211, USC-HSC, 1975 Zonal Ave, Los Angeles, CA 90089-9024. Articles and photographs accepted for publication will bear the contributor's name. There is no charge for reproduction and printing of color illustrations.*

©1999 American Medical Association. All rights reserved.
Downloaded From: http://archpedi.jamanetwork.com/ on 07/22/2014