SECTION EDITOR: ENID GILBERT-BARNESS, MD

Pathological Case of the Month

Eneida Rosario, MD; Mark L. Cohen, MD; Alan R. Cohen, MD; Michael L. Nieder, MD

THIS MALE INFANT was born at 41 weeks' gestation to a 20-year-old, gravida 3, para 2 woman with an unremarkable medical history, normal prenatal test results, and no smoking, drug use, or other harmful habits. Pregnancy was complicated by decreased fetal movements during the last week of gestation. An ultrasound performed the morning before delivery revealed severe hydrocephalus. A previous ultrasound performed at the 20th week showed no abnormalities. The infant was delivered by emergency cesarean section without complications or need for resuscitation. Apgar scores were 7 and 9 at 1 and 5 minutes, respectively. His birth weight was 4054 g (>95th percentile for age), length was 51 cm (75th percentile), and head circumference was 40 cm (>95th percentile). He was transferred to the neonatal intensive care unit for further evaluation and management.

On physical examination the infant had normal vital signs. He had marked macrocephaly, a full anterior fontanel measuring 5 × 4 cm and a full posterior fontanel measuring 5 × 3 cm. Results of the remainder of the examination were normal. Complete blood cell count, blood chemistry analysis, and results of coagulation studies were normal. Serum and cerebrospinal α_1-fetoprotein levels were markedly elevated at 7555 µg/L and 1028 µg/L, respectively. Serum quantitative human chorionic gonadotropin levels were in the normal range. Magnetic resonance imaging of the head (**Figure 1**) showed a multicystic mass located within the third ventricle.

The patient developed seizures on the third day of life and underwent radical resection of the intracranial mass on the following day. A 4-cm, grayish, heterogeneous tumor growing into the cavum septum pellucidum and third ventricle was resected. The surgical specimen consisted of 3 pieces of soft, tan and maroon, gelatinous tissue. Microscopic sections of the tumor are shown in **Figure 2** and **Figure 3**.

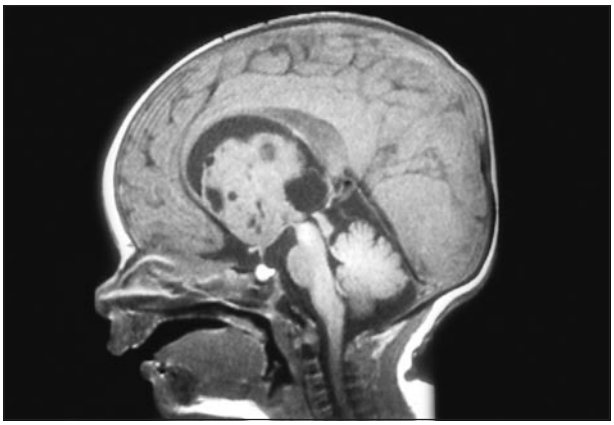

Figure 1.

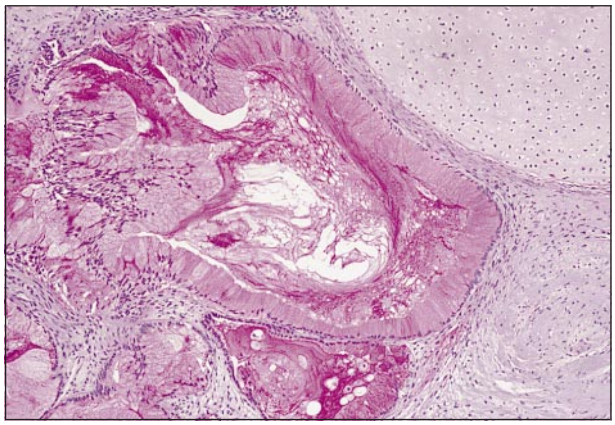

Figure 2.

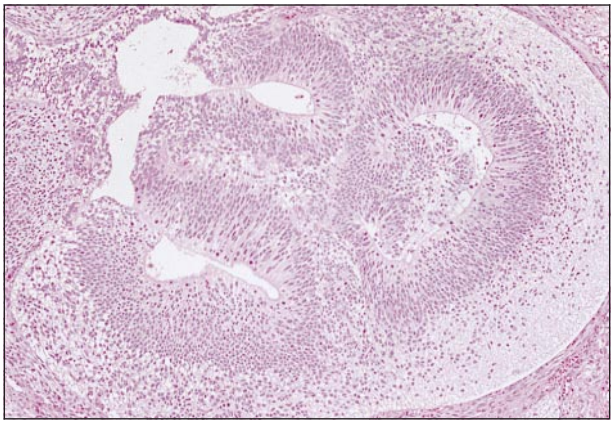

Figure 3.

©1999 American Medical Association. All rights reserved.
Downloaded From: http://archpedi.jamanetwork.com/ on 08/02/2014

Diagnosis and Discussion

Intracranial Immature Teratoma

Figure 1. *Magnetic resonance imaging of the head shows a mass measuring 4.2 cm in diameter with cystic contents and small areas of nodular and rim enhancement. The mass causes marked compression of the cortical mantle throughout the inferior parietal and temporal regions.*

Figure 2. *Multiple mature germ cell elements are seen within the resected tumor. Mature cartilage can be seen adjacent to respiratory-type epithelium (periodic acid–Schiff, original magnification ×40).*

Figure 3. *Much of the tumor is composed of primitive neuroectodermal cells. Focally, medulloepitheliomalike differentiation is present, with the tumor cells forming primitive neural tubes (hematoxylin-eosin, original magnification ×40).*

Congenital intracranial tumors are rare, accounting for 0.5% to 1.5% of all childhood brain tumors.[1] Data from the National Cancer Institute's Surveillance Epidemiology and End Results program suggest that the incidence of these tumors has increased during the past 20 years.[2]

The most common clinical presentation is macrocrania, hydrocephalus, and a bulging fontanel. Signs of increased intracranial pressure such as papilledema and nuchal rigidity are less frequent because of decompression through the cranial sutures. Other findings include paresis, cranial nerve deficits, convergence nystagmus (Parinaud syndrome), seizures, vomiting, and lethargy. A supratentorial location of the tumor is more common in infants than in older children. Differential diagnosis of supratentorial tumors includes astrocytoma, ependymoma, primitive neuroectodermal tumor, germ cell tumor, and choroid plexus papilloma. In a series studied at University of California–San Francisco, the most common brain tumor presenting or producing symptoms at birth was teratoma, occurring about 5 times more frequently than the second most common type, astrocytoma.[3]

In general, intracranial teratomas are extremely uncommon. Most are located in the pineal region, but about 20% are located in the suprasellar or infrasellar regions.[4] Histologically they are classified as mature, immature, or teratoma with malignant components based on the amount of tissue differentiation. They contain structures derived from all 3 germ cell layers. Immature teratomas may also contain primitive neural tissue.[5] They may produce plasma or cerebrospinal fluid markers such as α_1-fetoprotein and human chorionic gonadotropic hormone. Prenatal diagnosis has increased with the use of ultrasonography.[6]

Congenital intracranial teratomas have a poor prognosis. There are several cases reported in the literature of stillborn infants presenting with severe macrocephaly, history of polyhydramnios, and even skull rupture at delivery.[7-9] Most of these infants die within the first few months of life and the longest survival reported has been 1.5 years.[6]

Treatment includes radical surgical resection of the tumor, followed by either radiotherapy and/or chemotherapy. The extent of surgical resection is an important prognostic factor.[4] If the patient survives, radiotherapy is usually postponed until 24 to 36 months of age to avoid complications such as stunted growth, endocrine disturbances, and neuropsychologic problems.

Accepted for publication January 1, 1999.

Reprints: Eneida Rosario, MD, Department of Pediatrics, Rainbow Babies and Children's Hospital, 11100 Euclid Ave, Mailstop 6002, Cleveland, OH 44106.

REFERENCES

1. Rickert CH, Probst-Cousin S, Louwen F, Feldt B, Gullotta F. Congenital immature teratoma of the fetal brain. *Child Nerv Syst.* 1997;13:556-559.
2. Kenney LB, Miller BA, Gloecker-Reis LA, et al. Increased incidence of cancer in U.S. infants, 1980 to 1990 [abstract]. *Pediatr Res.* 1995;37:159A.
3. Raisanen JM, Davis RL. Congenital brain tumors. *Pathology (Phila).* 1993;2:103-116.
4. Castleberry RP, Cushing B, Perlman E, Hawkins EP. Germ cell tumors. In: Pizzo PA, Poplack DG, eds. *Principles and Practice of Pediatric Oncology.* 3rd ed. Philadelphia, Pa: Lippincott-Raven Publishers; 1997:921-945.
5. Salzman KL, Rojiani AM, Buatti J, et al. Primary intracranial germ cell tumors: clinicopathologic review of 32 cases. *Pediatr Pathol Lab Med.* 1997;17:713-727.
6. Ferreira J, Eviatar L, Schneider S, Grossman R. Prenatal diagnosis of intracranial teratoma, prolonged survival after resection of a malignant teratoma diagnosed prenatally by ultrasound: a case report and literature review. *Pediatr Neurosurg.* 1993;19:84-88.
7. Soares FA, Fischer SE, Reis MA, Soares EG. Massive intracranial immature teratoma: report of a case with polyhydramnios and intense pelvic pain. *Arq Neuropsiquiatr.* 1996;54:309-312.
8. Go JH, Kim TS, Cho SH. Massive intracranial teratoma: an autopsy case. *Yonsei Med J.* 1995;36:310-314.
9. Washbume JF, Magann EF, Chauhan SP, Fratkin JD, Morrison JC. Massive congenital intracranial teratoma with skull rupture at delivery. *Am J Obstet Gynecol.* 1995;173:226-228.

©1999 American Medical Association. All rights reserved.
Downloaded From: http://archpedi.jamanetwork.com/ on 08/02/2014