SECTION EDITOR: ENID GILBERT-BARNESS, MD

Pathological Case of the Month

Julie R. Kenner, MD, PhD; Leonard C. Sperling, MD

A 9-YEAR-OLD African American boy requested the cosmetic removal of 2 alopecic scalp lesions that had been present since birth (**Figure 1**). One lesion (**Figure 2**) was located on the posterior vertex of the scalp and consisted of a 10×10-mm circular atrophic scar devoid of any hair. The second lesion (**Figure 3**) was a 45×17-mm, lancet-shaped patch on the left temporal area of the scalp, with the point of the lesion directed superiorly and posteriorly. There were fine vellus hairs, but no terminal hairs within the zone of alopecia. The boy was otherwise healthy and had no family history of hair disorders.

Both lesions were surgically excised, and a 4-mm punch biopsy of each tissue specimen was processed both transversely and vertically (**Figure 4** and **Figure 5**).

From the Dermatology Service, Walter Reed Army Medical Center, Washington, DC (Dr Kenner); and the Department of Dermatology, Uniformed Services University of the Health Sciences, Bethesda, Md (Dr Sperling).

Figure 1.

Figure 2.

Figure 3.

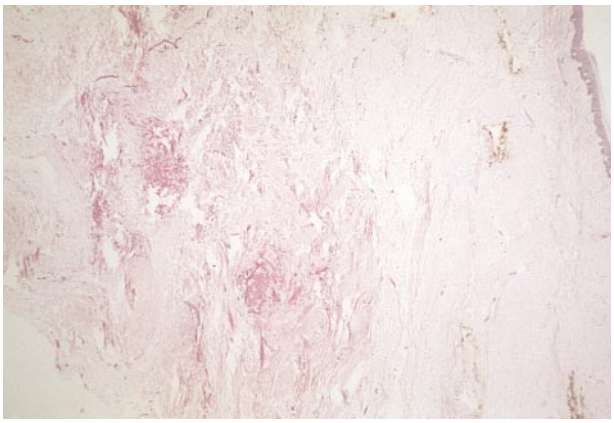

Figure 4.

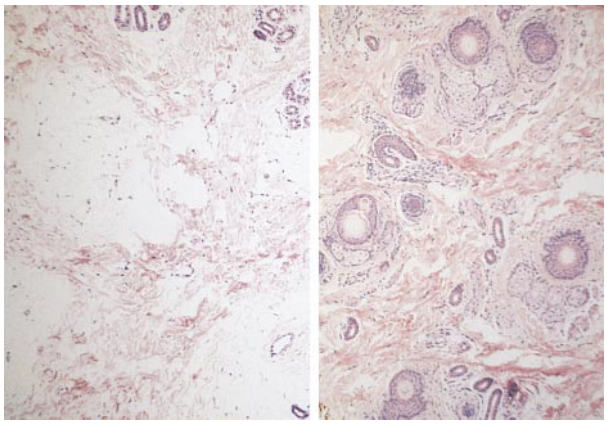

Figure 5.

©1998 American Medical Association. All rights reserved.
Downloaded From: http://archpedi.jamanetwork.com/ on 09/03/2015

Diagnosis and Discussion

Temporal Triangular Alopecia and Aplasia Cutis Congenita

Figure 1. *A view of 2 congenital alopecic scalp lesions in a 9-year-old African American boy.*

Figure 2. *A 10 × 10-mm circular atrophic scar of aplasia cutis congenita, located on the posterior vertex of the scalp and completely devoid of hair. This is the typical location for this congenital lesion.*

Figure 3. *A 45 × 17-mm, lancet-shaped patch of temporal triangular alopecia on the left temporal area of the scalp. Fine, vellus hairs cover the lesion.*

Figure 4. *Photomicrographic view of a vertical section of aplasia cutis congenita showing extensive dermal fibrosis and absence of adrenal structures (hematoxylin-eosin, original magnification ×20).*

Figure 5. *Photomicrographic view of a transverse section of temporal triangular alopecia. Left, Level of reticular dermis showing miniaturized vellus hairs (hematoxylin-eosin, original magnification ×40). Right, Level of subcutaneous fat readily demonstrating absence of terminal hair structures (hematoxylin-eosin, original magnification ×40).*

Aplasia cutis congenita is a relatively common, congenital, localized absence of skin, usually occurring on the scalp. Although clinical presentation may vary at birth, mature lesions of aplasia cutis congenita are atrophic scars devoid of adnexal structures.[1] Most commonly, aplasia cutis congenita is an isolated finding that is not associated with other abnormalities.

Temporal triangular alopecia (TTA) is a stable form of nonscarring alopecia, usually diagnosed between the ages of 2 and 6 years.[2] In congenital TTA, the lesions are present at birth.[3] It is characterized by an oval- or lancet-shaped alopecic patch located unilaterally or bilaterally in the temporofrontal area, with the pointed tip of the lesion directed superiorly and posteriorly. Although infrequently reported, TTA is believed to be relatively common. There seems to be no sexual preference for the condition, but it has not yet, to our knowledge, been reported in African Americans.[2] We also know of no reports of TTA associated with other scalp disorders.[4]

Histopathologically, TTA is characterized by an absence of inflammation and a normal number of hairs that are all miniaturized.[2,4] The abnormal histologic condition of this lesion is best evaluated by transverse section, where the number and type of hairs can be quantified. The normal number of scalp hairs on a 4-mm punch biopsy specimen transverse section is 20 to 40 hairs, with a terminal-vellus ratio of 2:1 to 4:1.[4,5]

To the best of our knowledge, this case represents the first incidence of TTA in an African American, and the first report of the simultaneous occurrence of aplasis cutis congenita and TTA.

Accepted for publication July 14, 1998.

The views expressed herein are those of the authors and do not necessarily reflect the views of the US Army or the US Department of Defense.

Corresponding author: Julie R. Kenner, MD, PhD, Dermatology Service, Department of Medicine, Tripler Army Medical Center, 1 Jarrett White Rd, Honolulu, HI 96859-5000.

REFERENCES

1. Frieden IJ. Aplasia cutis congenita: a clinical review and proposal for classification. *J Am Acad Dermatol.* 1986;14:646-660.
2. Trakimas C, Sperling LC, Skelton HG, Smith KJ, Buker JL. Clinical and histologic findings in temporal triangular alopecia. *J Am Acad Dermatol.* 1994;31:205-209.
3. Feuerman EJ. Congenital temporal triangular alopecia. *Cutis.* 1981;28:196-197.
4. Sperling LC. Evaluation of hair loss. *Curr Probl Dermatol.* 1996;8:101-136.
5. Sperling LC. Hair anatomy for the clinician. *J Am Acad Dermatol.* 1991;25:1-17.

©1998 American Medical Association. All rights reserved.
Downloaded From: http://archpedi.jamanetwork.com/ on 09/03/2015