

SECTION EDITOR: ENID GILBERT-BARNES, MD

Pathological Case of the Month

Juan C. Sanchez, MD; Janine E. Sanchez, MD

A 15-YEAR-OLD black girl presented with complaints of intermittent vomiting, abdominal pain, and vaginal bleeding during the past month. She gave a history of having been raped 2 months earlier.

On pelvic examination, the uterine size was consistent with a 12-week pregnancy. Her last menstrual period had occurred 10 weeks earlier. Medical history was noteworthy only for easily controlled asthma. She was taking no medications. The urine pregnancy test results were positive. β -Human chorionic gonadotropin (hCG) concentration in blood was 673 160 IU/L (normal for this stage, <200 000 IU/L). Abdominal ultrasound showed a 10.6 \times 7.0 \times 10.0-cm heterogeneous mass involving the uterus and containing cystic areas.

Suction dilatation and curettage were done. A brownish-tan, irregularly shaped, membranous, spongy mass with multiple translucent, membranous cysts was removed (**Figure 1** and **Figure 2**). During the procedure, the patient had a narrow complex tachycardia with a heart rate in the 180 range (prior to surgery, 95). The ECG revealed sinus tachycardia (130-150 /min) with a short PR interval and a delta wave consistent with a diagnosis of Wolff-Parkinson-White syndrome (WPW).

Because of the sinus tachycardia, hematocrit and thyroid function tests were ordered. The hematocrit had decreased to 0.18, from a level of 0.39 before surgery. The patient was given 1 U of packed RBCs.

The thyroid function tests revealed the following values: thyroxine (T_4), 464 nmol/L (36.2 μ g/dL) (normal range, 64-144 nmol/L [5.0-11.2 μ g/dL]); triiodothyronine (T_3) uptake, 0.225 (normal range, 0.245-0.39); free thyroxine index (FTI), 8.15 (normal range, 1.75-3.23); and thyrotropin (TSH), <0.01 mU/L (normal range, 0.3-4.0 mU/L). The β -hCG level fell to 82 824 IU/L 2 days after surgery.

Pediatric Endocrinology Service was consulted 3 days after the surgery when the thyroid function test results became available. The patient then had no signs of hyperthyroidism, except for a heart rate of 120 and a wide pulse pressure of 128/50 mm Hg. The thyroid was not palpable. No nodules or Delphian node was palpated. She had no eye abnormalities or resting tremor of the tongue or the extremities. She reported no symptoms of hyperthyroidism before or after surgery, except occasional tachycardia (possibly due to the undiagnosed WPW). Bowel movements were normal. No antithyroid medication was given.

Four days after the surgery, β -hCG concentration was 21 330 IU/L and thyroid function test values were T_4 , 246 nmol/L (19.2 μ g/dL); T_3 uptake, 0.27 FTI, 5.2; T_3 , 29 nmol/L (normal range, 1.2-2.9 nmol/L); and TSH, <0.01 mU/L. The patient was discharged home feeling well.

Repeated β -hCG concentration 5 days later was 957 IU/L, decreasing to 218 IU/L after 1 more week. One month after the surgery, the β -hCG level was 16 IU/L.

At 3 weeks after initial presentation, she remained clinically euthyroid. Her T_4 level was 101 nmol/L (7.9 μ g/dL); T_3 , 1.92 nmol/L; and TSH, 0.99 mU/L.

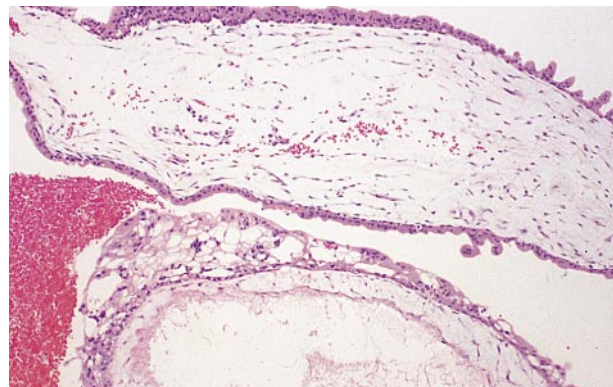


Figure 1.

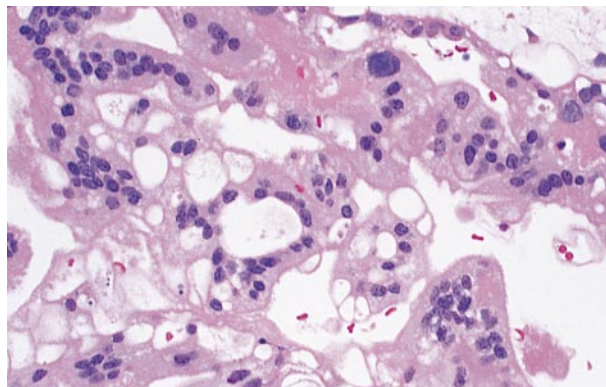


Figure 2.

From the Department of Pediatrics, University of Miami School of Medicine, Miami, Fla.

Diagnosis and Discussion

Hyperthyroidism With a Hydatidiform Mole

Figure 1. Hydropic chorionic villi with cisternae formation (hematoxylin-eosin, original magnification $\times 4$).

Figure 2. Trophoblastic proliferation (hematoxylin-eosin, original magnification $\times 20$).

The mass was a hydatidiform mole (HM). Microscopic appearance was characterized by markedly swollen chorionic villi with apparently empty cisternae resulting from dissociation of loose villous connective tissue and diffuse trophoblastic hyperplasia. Recognizable vascular elements were rarely seen.

HMs occur in approximately 1 in 1000 pregnancies,¹ but are rarely seen by pediatricians. The incidence of HMs in teenagers is 1.5- to 2-fold greater than in adult females.¹ HMs are due to abnormal growth of the chorionic villi. An HM may be complete or partial. A complete HM has no fetal or normal placental tissue; a partial HM has fetal and/or placental tissue combined with the mole. Moles occur when a single 23,X sperm fertilizes an ovum without a nucleus, and then the chromosomes double. Thus, most moles have a karyotype of 46,XX and all the chromosomes are paternal in origin. The abnormal development seems due to the lack of maternal chromosomal contribution to the embryo.²

Patients with HMs typically present with vaginal bleeding but may have hyperemesis and other signs of early pregnancy. The β -hCG concentrations in blood usually exceed 200 000 IU/L. Uterine size may be large for the stage of pregnancy. Whether complete or partial, HMs often create complications.

Hyperthyroidism is due to stimulation of the thyroid by hCG. The hCG is a glycoprotein hormone produced by trophoblastic tissue and composed of a unique β -subunit and an α -subunit that is similar to that of pituitary glycoprotein hormones, including TSH. Weak thyrotropic activity is seen with hCG ≈ 0.04 to $0.5 \mu\text{IU}$ bovine TSH/IU hCG or $0.52 \pm 0.35 \mu\text{IU}$ human TSH/IU hCG.^{3,4} On a molar basis, hCG is 1/4000 as potent as human TSH in the TSH bioassay.⁵ Unlike normal pregnancies with β -hCG levels $<100\,000$ IU/L, in molar pregnancies values are often $>200\,000$. As the hCG level increases, its thyrotropic activity becomes more notable and the thyroid sufficiently stimulated to become hyperfunctioning. However, there is no direct correlation between the β -hCG and T_4 or T_3 levels (possibly because only a fragment of β -hCG and not the total β -hCG is measured on most assays). Therefore, the degree of elevation of the thyroid hormones cannot be predicted by the β -hCG level. The pituitary will decrease TSH production in response to the elevated T_4 and T_3 values, and the TSH level may be undetectable, as in Graves disease.

Teenagers have an increased risk of molar pregnancies. They will often deny or be unaware of their pregnancy and may present to their pediatrician reporting only vaginal bleeding or abdominal pain. When suspected, it is important to include laboratory assessment of thyroid function prior to surgery as signs and symptoms of hyperthyroidism may be subtle and masked by those due to the

pregnancy. The complications that occur with HMs may also obscure the findings associated with hyperthyroidism. Even classic manifestations of thyrotoxicosis may be attributed to other complications if hyperthyroidism is not suspected. The thyroid itself usually appears normal, and the characteristic eye findings of Graves disease are absent.

Results of thyroid function tests often take 1 or 2 days to become available if not done emergently. Removal of the HM is usually scheduled soon after its diagnosis. Due to the undetected hyperthyroidism, the patient may become symptomatic with tachyarrhythmia, hyperthermia, and high-output cardiac failure and may even progress to potentially fatal thyroid storm during the surgical procedure.⁶ So, some patients may benefit from β -blockers and/or iodine administration prior to HM evacuation, both to control symptoms possibly present as well as to prevent other serious consequences, including thyroid storm. Propylthiouracil and methimazole usually take several days to become effective and are not appropriate for treatment in these cases.

Removing the HM, the source of hCG is gone and medication not needed. The β -hCG declines, as do the T_4 and T_3 levels; correspondingly TSH levels increase. Typically, the thyroid hormone levels return to normal in several weeks (perhaps 1 wk since the half-life of T_4 is 7 days), as will those of β -hCG. If thyroid function does not return to normal within a month, another cause is likely.

Suspect a patient seen with an HM to be hyperthyroid to prevent complications both before and at surgery. If the patient appears clinically hyperthyroid, consider HM as most likely and evaluate and manage to suit.

Accepted for publication May 5, 1997.

Reprints: Juan C. Sanchez, MD, Mailman Center for Child Development, 1601 NW 12th Ave, Miami, FL 33136.

REFERENCES

1. Hayashi K, Bracken MB, Freeman DH, et al. Hydatidiform mole in the United States (1970-1977): a statistical and theoretical analysis. *Am J Epidemiol.* 1982;115:67-77.
2. Thompson M, McInnes R, Willard H. The sex chromosomes and their abnormalities. In: Thompson M, McInnes R, Willard H, eds. *Thompson and Thompson: Genetics in Medicine*. ed 5. Philadelphia, Pa: WB Saunders;1991:245-246.
3. Carayon P, Lefort G, Nisula B. Interaction of human chorionic gonadotropin and human luteinizing hormone with human thyroid membranes. *Endocrinology.* 1980;106:1907-1916.
4. Pekary AE, Jackson IM, Goodwin TM, et al. Increased in vitro thyrotropic activity of partially sialated human chorionic gonadotropin extracted from hydatidiform moles of patients with hyperthyroidism. *J Clin Endocrinol Metab.* 1993;76:70-74.
5. Kenimer JG, Hershman JM, Higgins HP. The thyrotropin in hydatidiform moles is human chorionic gonadotropin. *J Clin Endocrinol Metab.* 1975;40:482-491.
6. Kim JM, Arakawa K, McCann V. Severe hyperthyroidism associated with hydatidiform mole. *Anesthesiology.* 1976;44:445-448.
7. Nagataki S, Mizuno M, Sakamoto S, et al. Thyroid function in molar pregnancy. *J Clin Endocrinol Metab.* 1977;44:254-263.
8. Norman RJ, Green-Thompson RW, Jialal I, et al. Hyperthyroidism in gestational trophoblastic neoplasia. *Clin Endocrinol.* 1981;15:395-401.
9. Twigg LB. Nonneoplastic complications of molar pregnancy. *Clin Obstet Gynecol.* 1984;27:199-209.
10. Mann K, Schneider N, Hoermarm R. Thyrotropic activity of acidic isoelectric variants of human chorionic gonadotropin from trophoblastic tumors. *Endocrinology.* 1986;118:1558-1566.