SECTION EDITOR: BEVERLY P. WOOD, MD

Radiological Case of the Month

Daniel B. Sobel, MD

A 450-G, WHITE male neonate was delivered at 24 weeks' gestation due to complications of severe pregnancy-induced hypertension. He was not fed and required mechanical ventilation and placement of umbilical artery and venous catheters. An initial chest radiograph showed changes of respiratory distress syndrome despite surfactant therapy and, in the abdomen, a lack of gas beyond the stomach. On the sixth day, a patent ductus arteriosus (PDA) was diagnosed and treated with intravenous indomethacin, and antibiotic treatment was begun. The PDA closed, noted on clinical and echocardiographic evaluation 5 days later. Combined treatment with dexamethasone and ranitidine were begun on day 9 for continued respiratory distress. A radiograph taken after endotracheal tube replacement showed a pneumoperitoneum (**Figure 1**). One day later, a radiograph was obtained for abdominal distention and again demonstrated free intraperitoneal air (**Figure 2**). The infant had previously been clinically and hemodynamically stable and had been weaned from mechanical ventilation and supplementary oxygen.

Surgical placement of a percutaneous abdominal Penrose drain was performed. Intestinal contents were not recovered, nor were there signs of peritonitis or bleeding. A radiograph after introduction of diluted water-soluble contrast material through a feeding tube is shown (**Figure 3**). Peritoneal cultures later grew *Staphylococcus* coagulase-negative species. The gastrointestinal (GI) leak spontaneously resolved.

From the Division of Neonatology, Department of Pediatrics, Maine Medical Center, Portland.

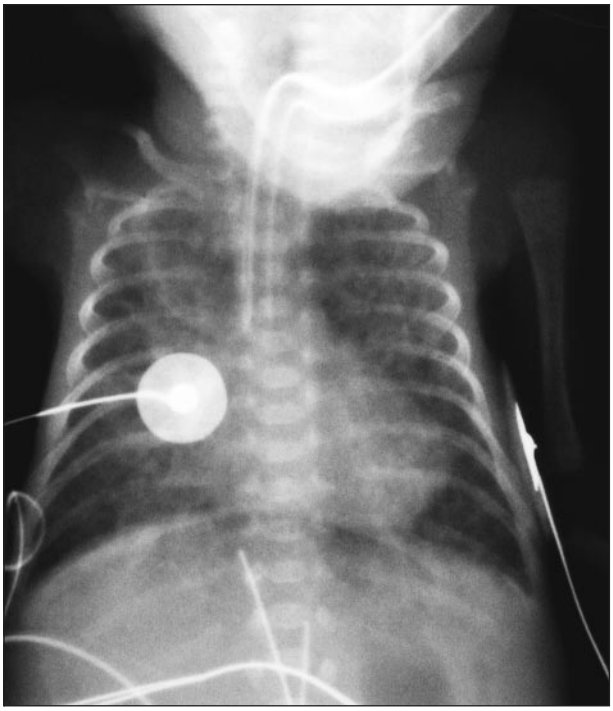

Figure 1.

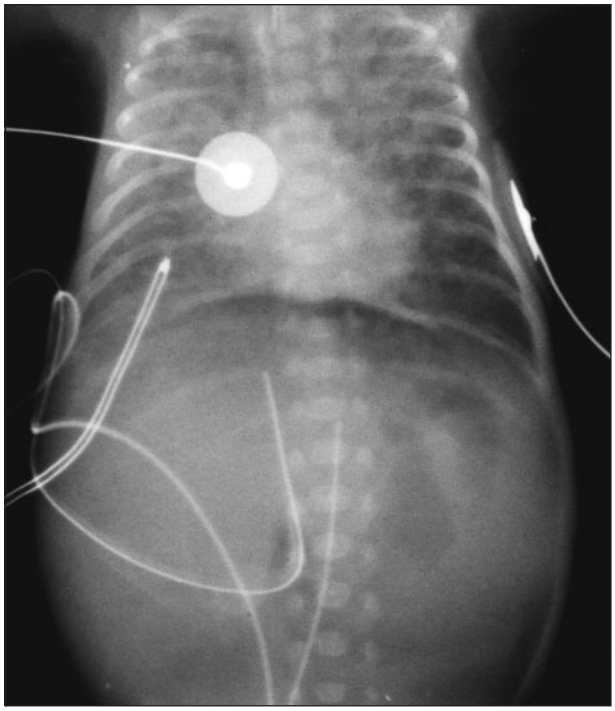

Figure 2.

©1998 American Medical Association. All rights reserved.
Downloaded From: http://archpedi.jamanetwork.com/ on 05/30/2015

Denouement and Discussion

Neonatal Gastric Perforation

Figure 1. *Free intraperitoneal air is present below the diaphragm. Evidence of respiratory distress syndrome and early bronchopulmonary dysplasia is seen in the lungs.*

Figure 2. *Pneumoperitoneum without bowel wall pneumatosis or portal vein gas is observed.*

Figure 3. *Extravasation of oral contrast material into the peritoneal cavity is present. The Penrose drain in the right lower quadrant is outlined.*

Multiple causes of isolated neonatal gastric perforation include (1) spontaneous and mechanical disruptions[1,2]; (2) traumatic, secondary to feeding-tube placement or vigorous respiratory resuscitation[2]; (3) drug associated, eg, with dexamethasone for neonatal chronic lung disease[3-5] or after indomethacine for treatment of PDA[6,7]; (4) focal GI perforation or necrotizing enterocolitis (NEC)[8]; (5) isolated gastric ischemia secondary to hypoxia[9]; and (6) congenital absence of bowel wall muscle.[10]

Spontaneous gastric perforations usually occur within week 1 of life and are typically in full-term or large premature infants. Overdistention of the stomach with consequent rupture has been demonstrated in infants with gastric outlet obstruction. Other conditions associated with mechanical obstruction from functional gastric obstruction include pyloric atresia, duodenal obstruction with atresia or volvulus, tracheoesophageal fistula, left diaphragmatic eventration, and negative pressure ventilation.[1] Reports of perforation associated with esophageal intubation, mechanical ventilation, or direct perforation with feeding tubes are reported with premature and very ill infants.[11,12]

Corticosteroids[3,4] and nonsteroidal anti-inflammatory drugs[6,13] have a known ulcerogenic potential. Nonsteroidal anti-inflammatory drugs may induce erosive gastritis, linear ulcerations, and gross or occult hemorrhage due to inhibition of prostaglandin synthase and local impairment of ion transport. Corticosteroids are ulcerogenic by decreasing mucosal resistance to peptic digestion. Inhibition of surrounding inflammation may mask the symptoms of ulceration leading to a "silent" perforation.

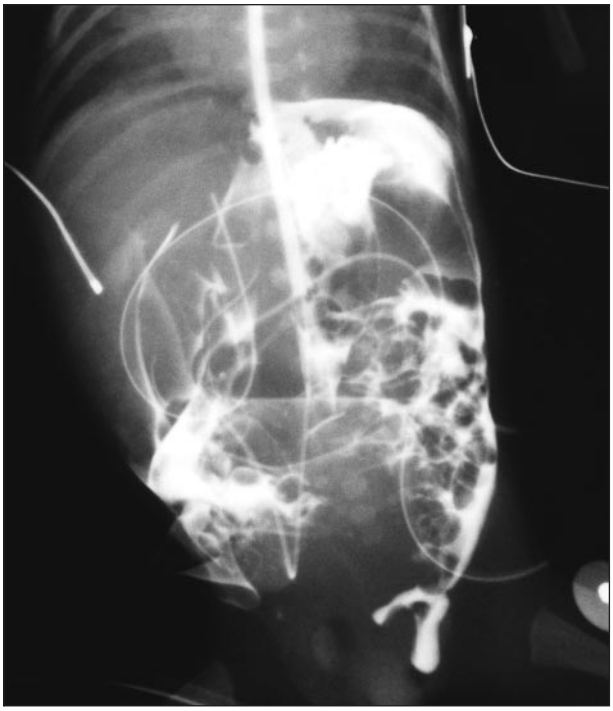

Figure 3.

This infant had never been fed and was receiving an H_2-receptor antagonist at the time of the perforation. Use of these agents has been proposed to prevent the complication of steroid-associated ulcers from increased acid secretion.[4,14]

Focal GI perforations unassociated with NEC occurring in very low-birth weight neonates have been increasingly reported and may involve the stomach. Expected signs or symptoms of NEC or evidence of gastroesophageal bleeding are usually absent. Isolated gastric ischemia leading to perforation is not a likely explanation because of the stomach's ample blood supply. Absence of gastric muscle, advanced as a cause of gastric perforation resulting from microscopic gaps in the muscularis and surrounding normal mucosa and submucosa, may be a normal variant.

The exact origin of this gastric perforation remains unknown; multiple contributory factors were functional gastric obstruction, use of dexamethasone and indomethacin, a feeding tube, extremely low birth weight, and needed ventilatory support.

Although temporary gastric sealing was documented, 2 subsequent perforations developed. The latest perforation, 26th day of life, was associated with a large PDA, respiratory and metabolic acidosis, and hemodynamic instability after which support was ended. Autopsy permission was denied.

Accepted for publication December 24, 1996.

Reprints: Daniel B. Sobel, MD, Division of Neonatology, Department of Pediatrics, Maine Medical Center, 22 Bramhall St, Portland, ME 04102.

REFERENCES

1. Holgersen LO. The etiology of spontaneous gastric perforation of the newborn: a reevaluation. *J Pediatr Surg.* 1981;16:608-613.
2. Rosser SB, Clark CH, Elechi EN. Spontaneous neonatal gastric perforation. *J Pediatr Surg.* 1982;17:390-394.
3. Ng PC, Brownlee KG, Dear PRF. Gastroduodenal perforation in preterm babies treated with dexamethasone for bronchopulmonary dysplasia. *Arch Dis Child.* 1991;66:1164-1166.
4. O'Neil EA, Chwals WJ, O'Shea MD, Turner CS. Dexamethasone treatment during ventilator dependency: possible life-threatening gastrointestinal complications. *Arch Dis Child.* 1992;67(special issue):10-11.
5. St Vil D, LeBouthillier G, Luks FL, Bensoussan AL, Blanchard H, Youssef S. Neonatal gastrointestinal perforations. *J Pediatr Surg.* 1992;27:1340-1342.
6. Grosfeld JL, Chaet M, Molinari F, et al. Increased risk of necrotizing enterocolitis in premature infants with patent ductus arteriosus treated with indomethacin. *Ann Surg.* 1996;224:350-357.
7. Gray PH, Pemberton PJ. Gastric perforation associated with indomethacin therapy in a preterm infant. *Aust Pediatr J.* 1980;16:65-66.
8. Mintz AC, Applebaum H. Focal gastrointestinal perforations not associated with necrotizing enterocolitis in very low-birth weight neonates. *J Pediatr Surg.* 1993; 28:857-860.
9. Lloyd JR. The etiology of gastrointestinal perforation in the newborn. *J Pediatr Surg.* 1969;4:77-84.
10. Herbur PA. Congenital defect in the musculature of the stomach with rupture in a newborn infant. *Arch Pathol.* 1943;36:91-94.
11. Tan CEL, Kiely EM, Agrawal M, Brerton RJ, Spitz L. Neonatal gastrointestinal perforation. *J Pediatr Surg.* 1989;24:888-892.
12. Chen JW, Wong BWK. Intestinal complications of nasojejunal feeding in low-birth weight infants. *J Pediatr.* 1974;85:109.
13. Lewis JH. Gastrointestinal injury due to medicinal agents. *Am J Gastroenterol.* 1986;81:819-834.
14. Kelly EJ, Chatfield SL, Brownlee KG, Ng PC, Newell SJ, Primrose JN. The effect of intravenous ranitidine on the intragastric pH of preterm infants receiving dexamethasone. *Arch Dis Child.* 1993;69(special issue):37-39.

©1998 American Medical Association. All rights reserved.
Downloaded From: http://archpedi.jamanetwork.com/ on 05/30/2015