

SECTION EDITOR: ENID GILBERT-BARNES, MD

Pathological Case of the Month

Rachel Ray MD; Diane Debich-Spicer; Orestes Borrego, MD; Enid Gilbert-Barnes, MD

THE PATIENT was a full-term female infant born to a mother with genital condylomas. The infant had a hoarse cry from birth. At 5 months of age, she was brought to the emergency department with respiratory distress and aphonia. Her condition was diagnosed and she was treated for a pertussis-like illness. At 6 months of age, she returned with respiratory distress and stridor. She required intubation. Multiple nodular lesions in the subglottic area were resected by laser. The gross and microscopic appearances are shown in **Figure 1**, **Figure 2**, and **Figure 3**. The lesions were recurrent. She required a tracheostomy at 10 months of age to maintain airway patency. The lesions had spread to her bronchi and lungs. She undergoes laryngoscopy and excision of the lesions every 2 to 3 weeks. There

are multicavitary cystic lesions in the lungs bilaterally as seen on the computed tomographic scan (**Figure 4**).

From the Departments of Pediatrics (Drs Ray and Gilbert-Barnes) and Pathology (Ms Debich-Spicer and Drs Borrego and Gilbert-Barnes), University of South Florida, Tampa.

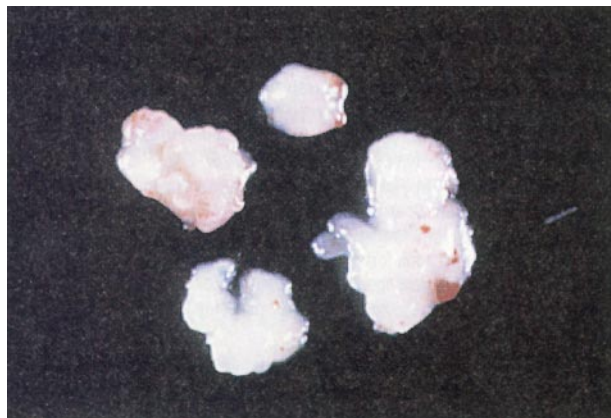

Figure 1.

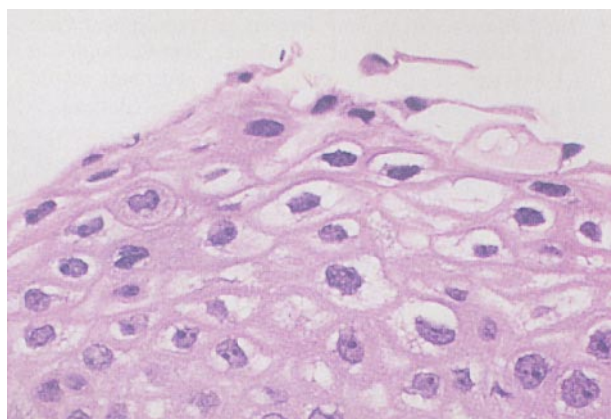


Figure 2.

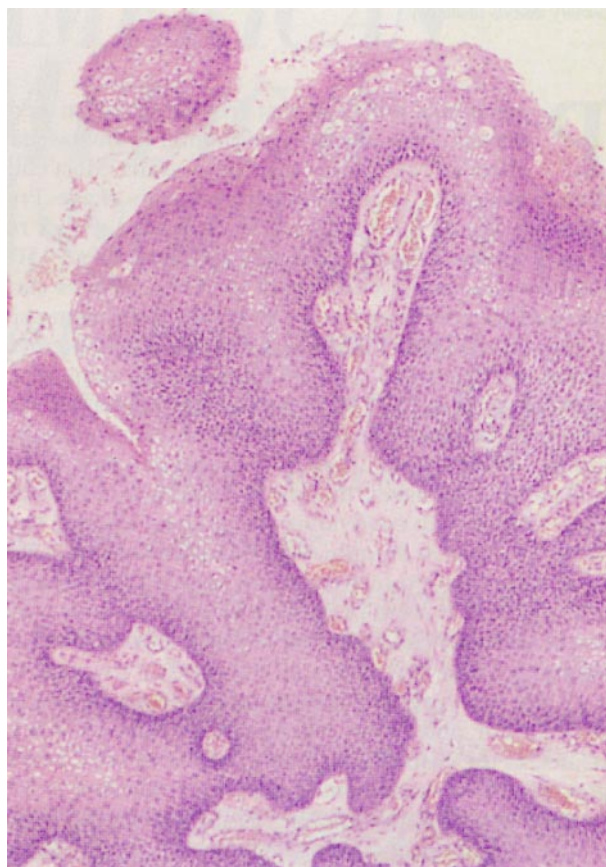


Figure 3.

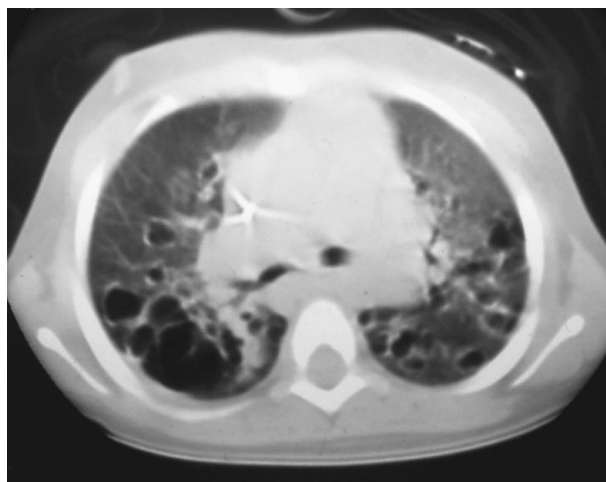


Figure 4.

Diagnosis and Discussion

Recurrent Respiratory Papillomatosis

Figure 1. Multiple surgically removed papillomas.

Figure 2. Microscopic section. Squamous papilloma (original magnification $\times 40$).

Figure 3. Squamous papilloma showing koilocytosis due to human papillomavirus (original magnification $\times 250$).

Figure 4. A computed tomographic scan of the chest showing multicystic cavitory lesions bilaterally.

Papillomas are the most frequent benign neoplasms of the larynx in children.¹ Papillomas may affect any age group, including adults. Most children present with papillomas before 5 years of age. Presentation before 2 years of age is associated with a recurrent and progressive disease. Papillomas affect 1500 to 2000 infants and children in the United States each year and are now known to be caused by the human papillomaviruses (HPV); HPV-6 and HPV-11 are the most commonly identified types.²⁻⁴ These are the same types found in greater than 90% of genital condylomas. It is believed that these lesions are acquired from an affected mother. While greater than 50% of children with laryngeal papillomas have a history of maternal condylomas, most women with condylomas do not have affected children. The reason is unknown. Cesarean section seems to be somewhat protective.⁵ Adult and childhood laryngeal papillomas were previously believed to have a different pathogenesis, but new research now points to a common cause.^{3,6}

The most common presenting symptoms are hoarseness, stridor, and airway obstruction. Patients have been treated in the past for recurrent croup or asthma. Laryngoscopy, the investigation of choice, is indicated to rule out respiratory papillomatosis in any young child with symptoms of voice change, obstructive airway symptoms, or recurrent croup. While the larynx is the most commonly affected site, the lesions may spread to the lower airways in approximately 20% of cases, and in the rare case, to the lung's parenchyma. Increased risk of spread to the lower respiratory tract has been noted with placement of a tracheostomy, and therefore, such placement should be avoided for as long as possible. The clinical course varies from spontaneous remission to ruthless progression and the associated complications.⁷ In some, malignant degeneration to squamous cell carcinoma may occur. Once thought to uniformly regress during puberty, this has not been observed by some investigators.⁸

The treatment of respiratory papillomatosis is frustrating, as lesions are frequently recurrent and relentless. Surgical excision is the only definitive therapy. Most investigators use the carbon dioxide laser. Other therapies include interferon, isotretinoin, antibiotics, antiviral agents, hormones, steroids, podophyllin, and anti-metabolites (fluorouracil and methotrexate). Interferon has proven to be the most helpful.

Prognosis is affected by age at onset. The earlier the onset, the greater the likelihood of lower airway involvement. However, progressive disease can even occur in adults. A spontaneous remission is not infrequent. The factors associated with remission are not well understood. Childhood papillomatosis may persist into adulthood. Squamous cell carcinoma may occur without previous irradiation in patients with a long history of recurrent respiratory papillomatosis.⁹

Accepted for publication December 18, 1996.

Corresponding author: Enid Gilbert-Barness, MD, Department of Pathology, Tampa General Hospital, PO Box 1289, Tampa, FL 33061.

REFERENCES

1. Pransky SM, Seid AS. Tumors of the larynx, trachea and bronchi. In: Bluestone CD, Stool SE, eds. *Pediatric Otolaryngology*. 2nd ed. Philadelphia, Pa: WB Saunders Co; 1990:1215-1218.
2. Dickens P, Srivastava G, Loke SL, Larkin S. Human papillomavirus 6, 11 and 16 in laryngeal papillomas. *J Pathol*. 1991;165:243-246.
3. Gale N, Poljak M, Kabic V, Ferfuga D, Fischinger J. Laryngeal papillomatosis: molecular, histopathological and clinical evaluations. *Virchows Arch (Berlin)*. 1994; 425:291-295.
4. Smith EM, Pignatari SSN, Gray SD, Haugen TH, Turek LP. Human papilloma virus infection in papillomas and nondiseased respiratory sites of patients with recurrent respiratory papillomatosis using the polymerase chain reaction. *Arch Otolaryngol Head Neck Surg*. 1993;119:554-557.
5. Shah K, Haskins K, Polk F, Shah F, Abbey H, Abramson A. Rarity of cesarean delivery in cases of juvenile-onset respiratory papillomatosis. *Obstet Gynecol*. 1986;68:795-799.
6. Lindeberg H. Laryngeal papillomas: histomorphometric evaluation of multiple and solitary lesions. *Clin Otolaryngol*. 1991;19:257-260.
7. Anderson KC, Roy TM, Fields CL, Collins LC. Juvenile laryngeal papillomatosis: a new complication. *South Med J*. 1993;86:447-449.
8. Doyle DJ, Gianoli GJ, Espinola T, Miller RH. Recurrent respiratory papillomatosis: juvenile versus adult forms. *Laryngoscope*. 1994;104:523-527.
9. Simma B, Burger R, Uehlinger J, et al. Squamous cell carcinoma arising in a non-irradiated child with recurrent respiratory papillomatosis. *Eur J Pediatr*. 1993; 152:776-778.

Submissions

The Editors welcome contributions to Pathological Case of the Month, Picture of the Month, and Radiological Case of the Month. Those who wish to contribute should send their manuscripts to Dr Gilbert-Barness (Pathological Case of the Month), Department of Pathology, Tampa General Hospital, University of South Florida, Davis Island, Tampa, FL 33606; Dr Tunnessen (Picture of the Month), The Children's Hospital of Philadelphia, 34th Street and Civic Center Boulevard, Philadelphia, PA 19104; or Dr Wood (Radiological Case of the Month), Department of Radiology, Children's Hospital Los Angeles, 4650 Sunset Blvd, Los Angeles, CA 90027. Articles and photographs accepted for publication will bear the contributor's name. There is no charge for reproduction and printing of color illustrations.