SECTION EDITOR: BEVERLY P. WOOD, MD

Radiological Case of the Month

Wolfgang Pumberger, MD; Peter Wiesbauer, MD

A 6-MONTH-OLD BOY was referred to our hospital for evaluation of a left upper quadrant abdominal mass. The infant was born of an uneventful pregnancy. Findings from several routine checkups after birth were normal. A few days before admission to the hospital, the mass, detected during a routine physical examination, was thought to be splenomegaly. There was no history of abdominal pain or fever. Physical examination disclosed an egg-sized, clearly definable, smooth, nontender mass in the left upper quadrant of the abdomen. The mass was unmovable.

Imaging procedures included an ultrasonographic and radiographic scan of the abdomen (**Figure 1**), and a urogram (**Figure 2**). Results of routine laboratory tests were normal. Tumor markers and catecholamine metabolites were determined by blood and urine samples. An operation easily removed a lobulated, well-encapsulated, retroperitoneal mass (**Figure 3**).

From the Division of Pediatric Surgery, University of Vienna (Dr Pumberger) and the Department of Radiology, St Anna Children's Hospital (Dr Wiesbauer), Vienna, Austria.

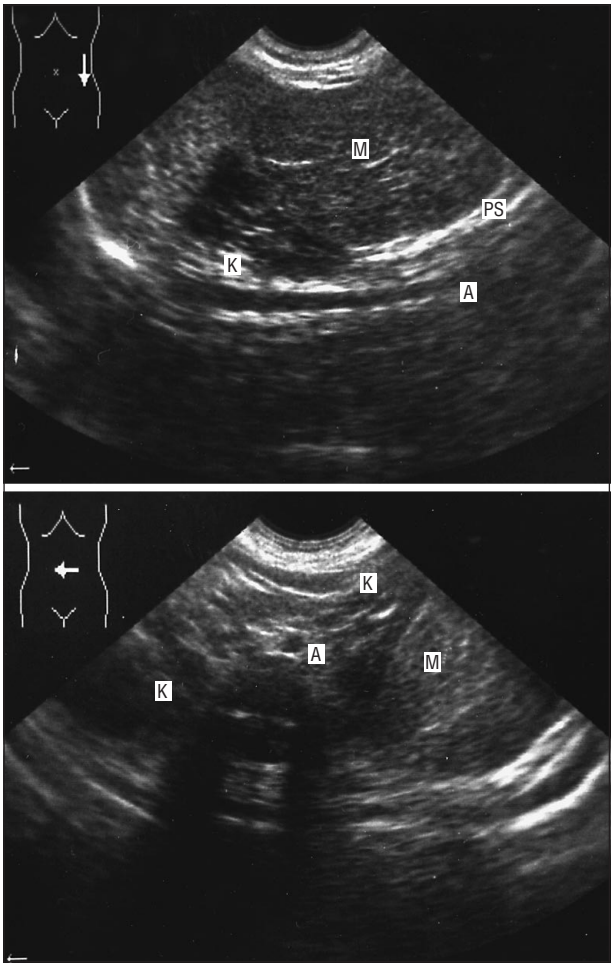

Figure 1.

Figure 2.

Figure 3.

©1998 American Medical Association. All rights reserved.
Downloaded From: http://archpedi.jamanetwork.com/ on 07/23/2014

Denouement and Discussion

Retroperitoneal Lipoma in a 6-Month-Old Infant

Figure 1. *Ultrasonogram. Top, Longitudinal view of the left side of the upper abdomen shows a 6×5×4-cm markedly echogenic mass with distinct margins to the kidney and the spleen. A indicates aorta; PS, psoas muscle; M, mass; and K, kidney. Bottom, Transverse view discloses medial and anterior displacement of the left kidney; the mass is clearly defined. A indicates aorta; M, mass; and K, kidney.*

Figure 2. *Radiograph of the abdomen and a urogram show a large homogeneous radiolucent mass in the left side of the upper abdomen. The small-bowel loops are displaced to the right side. The left kidney and the left ureter are displaced superomedially and anteriorly. There are no signs either of intrinsic renal involvement or of obstruction (note the double collecting system of the left kidney and ureter duplication).*

Figure 3. *A lobulated, well-encapsulated retroperitoneal fatty mass that was removed at operation.*

The retroperitoneum is one of the most frequent locations of solid tumors in children. Differential diagnosis includes a wide range of possible pathological origins although 90% are Wilms tumors or neuroblastomas.[1-3] Most of the remaining retroperitoneal masses, such as in multicystic kidney, hydronephrosis, or adrenal hemorrhage, can be excluded by ultrasonographic scanning.[1] Retroperitoneal lipomatous tumors are very rare in children. A reported series of 190 cases of retroperitoneal tumors included only 2 lipomas.[2] In general, these tumors are benign mature lipomas. Only a few tumors contain myxomatous liposarcomatous or well-differentiated liposarcomatous regions.[4]

Despite the rareness of retroperitoneal lipomas in children, the imaging characteristics are clearly defined.[5,6] Homogeneous radiolucency visualized on an abdominal radiograph is a characteristic finding. This sign is produced by the fatty content of the tumor. Calcification within the tumor has not been noted. A urogram demonstrates displacement of the ipsilateral kidney and medial deviation of the ureter; however, there are no signs of intrinsic renal involvement or obstruction. Lateral displacement of the ureters would suggest pelvic location of the retroperitoneal mass.[5]

An ultrasonogram shows a typical picture of a homogeneous echogenic mass: high echogenicity being characteristic for fat. The tumors show distinct margins and sometimes a capsule or septation is demonstrated. High echogenicity pattern is altered if there is a myxomatous or sarcomatous area within the tumor.[7]

The combination of a radiograph, an intravenous pyelogram, and an ultrasonogram is typically used to diagnose retroperitoneal lipomas. Occasionally, additional imaging procedures are used to get information that will affect management. A computed tomographic scan confirms the homogeneous fatty composition with Houndsfield numbers in the range of normal fat.[5,8,9] Magnetic resonance imaging will reveal an intense signal on T_1-weighted images. Previous use of angiography for lipomas showed the tumors to be hypovascular.[5]

Almost all reported lipomatous tumors of the retroperitoneum were easily and completely resected. The tumors were well encapsulated, without any invasion of adjacent structures. Retroperitoneal lipomas in children rarely exhibit a malignant potential. While most children have had a long follow-up without tumor recurrences,[5] the possibility of local recurrence after incomplete excision has been reported.[4]

Accepted for publication January 1, 1997.

Reprints: Wolfgang, Pumberger, MD, Division of Pediatric Surgery, University of Vienna, Währinger Gürtel 18-20, A-1090 Vienna, Austria.

REFERENCES

1. Teele RL, Share JC. The abdominal mass in the neonate. *Semin Roentgenol.* 1988; 23:175-184.
2. Hastings N, Pollock WF, Snyder W Jr. Retroperitoneal tumors in infants and children. *Arch Surg.* 1961;82:950-973.
3. Weitzner S, Blumenthal BI, Moynihan PC. Retroperitoneal lipoma in children. *J Pediatr Surg.* 1979;14:88-90.
4. Harvard BM. Retroperitoneal lipoma in children: report of case and review of literature. *J Urol.* 1953;70:159-166.
5. Bowen A, Gaisie G, Bron K. Retroperitoneal lipoma in children: choosing among diagnostic imaging modalities. *Pediatr Radiol.* 1982;12:221-225.
6. Young LW, Severson MV, Burke EC, Hattery RR. Radiological case of the month: retroperitoneal lipoma in a child. *AJDC.* 1980;134;83-84.
7. Behan M, Kazam E. The echographic characteristics of fatty tissues and tumors. *Radiology.* 1978;129:143-151.
8. Friedman AC, Hartman DS, Sherman J, Lautin EM, Goldman M. Computed tomography of abdominal fatty masses. *Radiology.* 1981;139:415-429.
9. Fisher MF, Fletcher BD, Dahms BB, Haller JO, Friedman AP. Abdominal lipoblastomatosis: radiographic, echographic, and computed tomographic findings. *Radiology.* 1981;138:593-596.

Submissions

The Editors welcome contributions to Pathological Case of the Month, Picture of the Month, *and* Radiological Case of the Month. *Those who wish to contribute should send their manuscripts to Dr Gilbert-Barness* (Pathological Case of the Month), *Department of Pathology, Tampa General Hospital, University of South Florida, Davis Island, Tampa, FL 33606; Dr Tunnessen* (Picture of the Month), *The American Board of Pediatrics, 111 Silver Cedar Ct, Chapel Hill, NC 27514-1651; or Dr Wood* (Radiological Case of the Month), *Department of Radiology, Childrens Hospital Los Angeles, 4650 Sunset Blvd, Los Angeles, CA 90027. Articles and photographs accepted for publication will bear the contributor's name. There is no charge for reproduction and printing of color illustrations.*

©1998 American Medical Association. All rights reserved.
Downloaded From: http://archpedi.jamanetwork.com/ on 07/23/2014